Papilledema & Idiopathic Intracranial Hypertension

Monterey Symposium
California Optometric Association 2019

Leonard V. Messner, OD, FAAO
Professor of Optometry
Vice President for Strategy & Institutional Advancement
Illinois College of Optometry

ILLINOIS EYE INSTITUTE

1

Financial Disclosure

- King Devick Technologies (scientific advisory board)
- Heidelberg Engineering (scientific advisory board)

2

34 y/o Woman

- **VA = 20/20, OU**
- **+ HA x 2 yrs.**
- **Normal neuro exam**
- **BMI: 39**

3

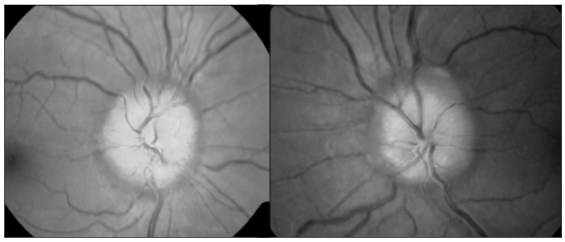

4

IIH - Key Points

- **Defining pseudotumor cerebri & IIH**
- **Pathogenesis of IIH**
- **Clinical features and neuroradiology**
- **Prognostic factors and management**
- **OCT analysis of papilledema**
- **Visual fields!**

5

INTRACRANIAL PRESSURE WITHOUT BRAIN TUMOR

DIAGNOSIS AND TREATMENT

WALTER E. DANDY, M.D.

BALTIMORE, MD.

DURING the past seven years there have gradually accumulated 22 cases in each of which the signs and symptoms of intracranial pressure have been indubitable, and yet in none has there been an intracranial tumor or a space occupying lesion of any kind. Almost without exception a clinical diagnosis of an unlocalized brain tumor has been made; but by ventriculography a brain tumor has been excluded. All of these patients have complained of headache, most of them of nausea, vomiting, diplopia, dizziness, many of loss of vision, and objectively in every instance there have been bilateral papilledema and usually hemorrhages in one or both eyegrounds to indicate, or at least strongly suggest, that intracranial pressure of advanced degree was present. And in each case the intracranial pressure has been objectively demonstrated and usually actually measured by ventricular or lumbar punctures; and finally the subsequent demonstration of pressure over a period of months or years is merely a matter of inspecting the site of the subtemporal decompression to which most of these patients were subjected for treatment. The increased intracranial pressure may last only a few months, but it at times persists five to seven years, and doubtless longer. Curiously, the decompression is almost never consistently at its maximum fullness but is intermittent, and the pressure may come and go with surprising rapidity—from one extreme to the other in a few minutes. The cause of the sudden changes—indeed the cause of the increased pressure at all—is unknown.

HISTORIES OF THE CASES CONSIDERED

Case 1.—Unit 10801 B. O. F. Age 21. *April 27 to May 14, 1927.*

Complaint.—*Headache and failing vision.*

Present Illness.—Three months ago patient awoke from her sleep smelling illuminating gas. She tried to get up, but fell and struck the back of her head. She vomited that day and the following day. There has been headache in the occipital region since then, worse on the left side, and she has vomited at times, especially in the morning. Since the original episode her vision has been failing; objects are indistinct and there are spots before her eyes. When she tries to read she becomes dizzy and the print melts away. Two weeks ago she thought she staggered, but this lasted only for a day.

Examination.—Patient is a normal appearing young woman of 21. There is papilledema of both eyegrounds, measuring two and one-half diopters on each side. There are no hemorrhages or exudates in either disk (Fig. 1). Visual acuity is 20/15 in each eye. Visual fields are normal.

Trephine and Air Injection.—April 30, 1927. Fluid spurted under pressure. The ventriculograms, however, were entirely normal. Wassermann of the cerebrospinal fluid was negative.

Operation.—Right subtemporal decompression, May 6, 1927. The dura was quite

692

Dandy WE *Ann Surg 1937*

6

J. Clin. Neuro-ophthalmol. 5: 55–56, 1985.

Editorial Comment

Whence Pseudotumor Cerebri?

In this issue of the Journal, Drs. Baker and Buncic present a case of pseudotumor cerebri and describe transient vertical ocular deviations as associated findings. If one recalls the classic criteria for the diagnosis of pseudotumor cerebri[1] as seen in Table 1, one might consider this as a fetishical suggestion.

TABLE 1
Dandy Criteria for the Diagnosis of Pseudotumor Cerebri (Modified)

1. Signs and symptoms of increased intracranial pressure (headaches, nausea, vomiting, transient obscurations of vision, papilledema)
2. No localizing neurologic signs otherwise (with the exception being unilateral or bilateral VI nerve palsies)
3. Cerebrospinal fluid which can show increased pressure but with no cytologic or chemical abnormalities otherwise
4. Ventricular system and posterior fossa normal on neurodiagnostic studies (ventriculography, angiography, contrast-enhanced computed tomography, but not myelography or computed tomography)

However, if one looks at the article by Drs. Baker and Buncic more closely, some additional points can be made. Their first patient was a 17-year-old girl who had a "transient diplopia" and bilateral lateral rectus weakness. They stated "When the horizontal deviation was neutralized a small, but definite incomitant vertical deviation was present as well, a right hypertropia of 10Δ in primary position, increasing to 20Δ in left gaze which increased to 25Δ in gaze down and right and disappeared in gaze up and right, simulating the pattern seen with inferior oblique overaction." One distinguishing feature of this case is that the vertical deviation in the primary position cannot be denied because the pattern of inferior oblique overaction increases in up gaze, and is less on down gaze, which is the opposite of the findings noted in this case. However, the point of this case report discussed here is that the authors describe a vertical deviation of 1 prism diopter in eccentric positions of up gaze and 3 prism diopters of left by prism cover test in primary position. It should be emphasized that it is difficult to see vertical deviations less than 2-3 diopters on careful objective examinations, and many examiners will not find a deviation of 1-2 diopters except by careful subjective tests. The point being, medically, is that the vertical deviations seen in this case are of questionable significance.

Dr. Walsh used to tell me that one could accept up to 2-3 prism diopters of a vertical deviation with a VI nerve palsy caution, but that any amount more than that was significant. I believe a petit mal seizure, which I saw in a case of Dr. Kenneth Kornblueth. Clinical Methods of Neuro-ophthalmology Examination, should be mentioned here. "Vertical diplopia or dysmetric pursuit. In dysmetric pursuit a vertical component is sometimes found in the form of a vertical jerk. Vertical diplopia is more than describes the red glass test results as follows:) "For example, in gaze to the left, the white image (the image belonging to the left eye) stands farther to the left, indicating a left abduction paresis of the right eye. The red image stands not only farther to the left but also lower, less peripheral. In gaze down and to the left, the white image stands to the left and higher than the red one. Such behavior would suggest that the right superior oblique and the left abducens of the right eye are involved, since the red images stand more 'peripheral' in vertical directions. The elevated red image in gaze up and to the left, and the depressed red image in gaze down and to the left, would suggest a paresis of the right inferior oblique and the right superior oblique, respectively. Such a triple combination seems strange, and yet this syndrome is not too rare. This phenomenon may be explained as follows:

"The left lateral rectus normally causes a certain mechanical inhibition of elevation and depression of the ipsilateral eye. Thus, the paresis of the left in gaze to the left—can be elevated and depressed more than normal: a hypermotility of the left eye upwards and downwards is present. This hypermobility of the left eye, in gaze to the left, causes the apparent left hypertropia and depression of the eye due to a paresis of the right inferior oblique and the right superior oblique. Therefore, a slight vertical distance between the images on gaze upwards or downwards within the field of action of the paretic muscles is seen. This vertical distance is not to be used for diagnosis of an additional paresis of a vertical motor muscle of the other eye." What is Dr. Kornblueth really saying here? On page 129, he states: "The lateral rectus . . . is mainly an abductor. In addition, it has a slight

March 1985 55

Smith JL *J Clin Neuro-ophthalmol 1985*

7

Revised Diagnostic Criteria for the Pseudotumor Cerebri Syndrome in Adults and Children

1. Signs and symptoms of increased intracranial pressure
2. Absence of localizing findings on neurologic examination
3. Absence of deformity, displacement, or obstruction of the ventricular system and otherwise normal neurodiagnostic studies, except for evidence of increased CSF pressure (>200 mm water); abnormal neuroimaging except for empty sella turcica, optic nerve sheath with filled out CSF spaces, and smooth-walled non-flow-related venous sinus stenosis or collapse should lead to another diagnosis
4. Awake and alert
5. No other cause of increased intracranial pressure present

For CSF opening pressure of 200-250 mm water required at least one of the following:

- Pulse synchronous tinnitus
- VI palsy
- Frisen grade II papilledema
- Echography for drusen-negative and no other disc anomalies mimicking disc edema present
- Magnetic resonance venography with lateral sinus collapse/stenosis preferably using auto-triggered elliptic centric-ordered technique
- Partially empty sella on coronal or sagittal views and optic nerve sheaths with filled out CSF spaces next to the globe on T2-weighted axial scans

Wall M, et al. *Neurology* 2014

8

Neuroradiology Findings with IIH

- **Empty sella**
- **Posterior scleral flattening**
- **Optic nerve distension**
- **Ectopic displacement of cerebellar tonsils**
- **Dural venous sinus stenosis**

9

Neuroradiology Findings with IIH

- **Empty sella**
- **Posterior scleral flattening**
- **Optic nerve distension**
- **Ectopic displacement of cerebellar tonsils**
- **Dural venous sinus stenosis**

10

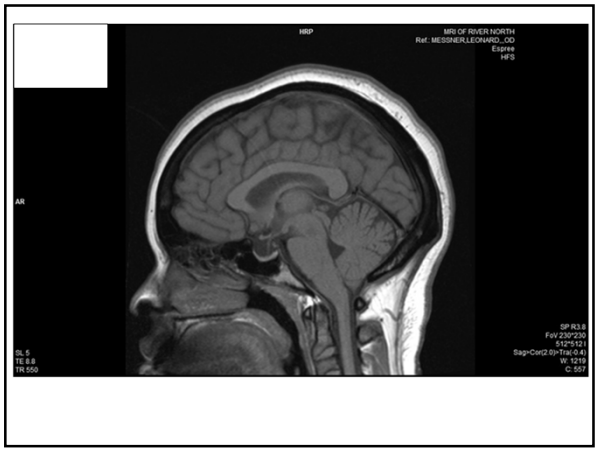

11

Neuroradiology Findings with IIH

- **Empty sella**
- **Posterior scleral flattening**
- **Optic nerve distension**
- **Ectopic displacement of cerebellar tonsils**
- **Dural venous sinus stenosis**

12

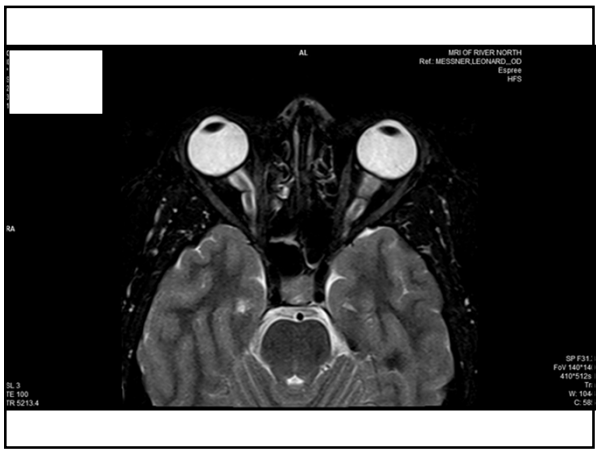

13

Neuroradiology Findings with IIH

- Empty sella
- Posterior scleral flattening
- Optic nerve distension
- Ectopic displacement of cerebellar tonsils (21%)
- Dural venous sinus stenosis

Aiken AH, et al. *Am J Neuroradiol* 2012

14

15

Neuroradiology Findings with IIH

- Empty sella
- Posterior scleral flattening
- Optic nerve distension
- Ectopic displacement of cerebellar tonsils
- Dural venous sinus stenosis (90%)

Farb RI, et al. *Neurology* 2003

16

27 y/o AA Woman

- c/o moderate, progressive headaches x 1-2 month
- Normal neurologic exam
- BVA:
  - 20/20 OD
  - 20/20 OS
- BMI: 58

17

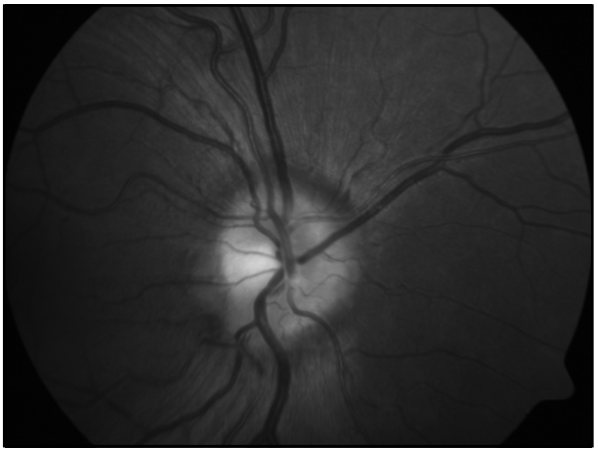

18

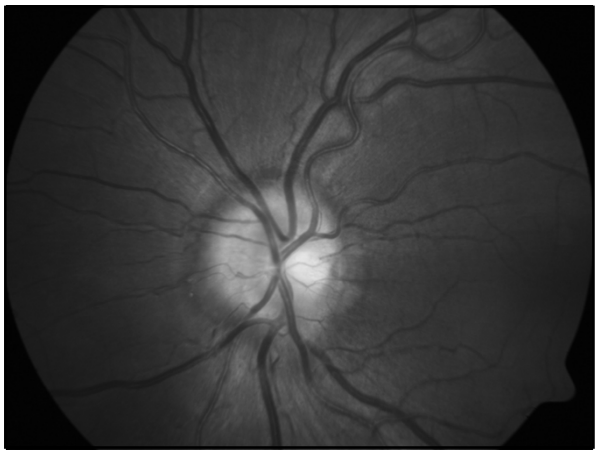

19

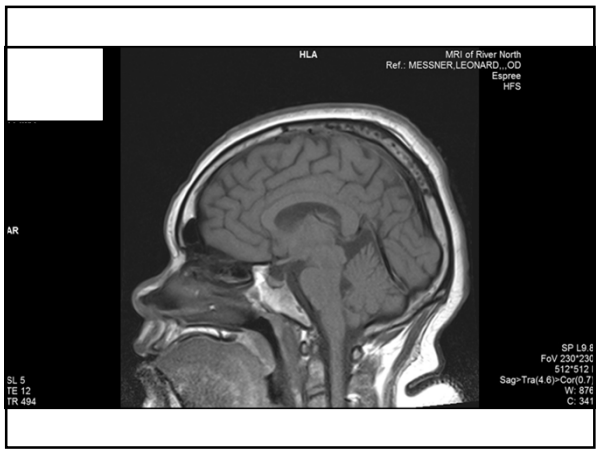

20

21

Epidemiology of IIH

- 85 - 90 % female
- 15 to 44 years
- Obesity
- MAI = 0.9-1.7/100,000
  - *7.9-20.2/100,000 if obese female 15-44 yrs.*

Giuseffi V, et al. *Neurology* 1991
Ireland B, et al. *Arch Neurol* 1990
Radhakrishnan K. et al. *Arch Neurol* 1993

22

Pathogenesis of IIH (???)

- Increased cerebral blood volume - *Raichle' 1978*
- Increased arachnoid resistance to CSF drainage - *Aisenberg' 1980*
- *Increased intra-abdominal pressure with cerebral venous hypertension - Sugerman' 2001*
- *Reduced CSF absorption by extracranial lymphatics – Johnston' 2006*

23

Baseline Clinical Profile (IIHTT)

- Headache (84%)
- Back pain (53%)
- Tinnitus (52%)
- Vision loss
  - Transient vision loss (68%)
  - Symptomatic vision loss (32%)
  - Visual fields (86% {5% > 15db})
    - Enlarged blind spot
    - Inferior arcuate defects

Wall M *JAMA Neurol* 2014

24

The rest of the story…

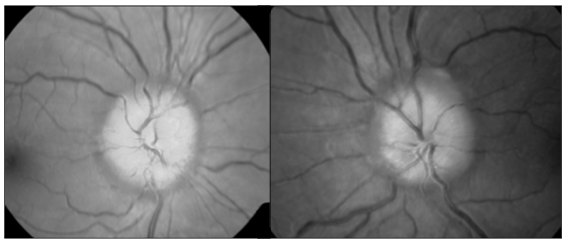

20/20 20/20

25

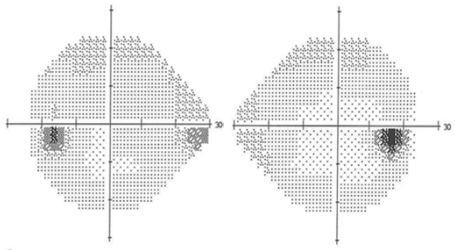

-2.54 db -4.07 db

26

12 mos later…

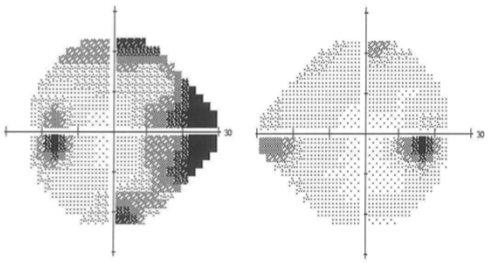

-11.13 db -3.22 db

27

19 mos later…

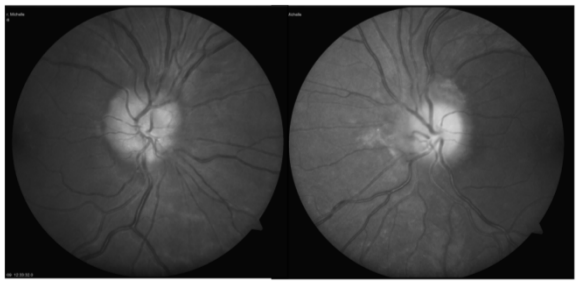

20/20 20/30

28

19 mos later…

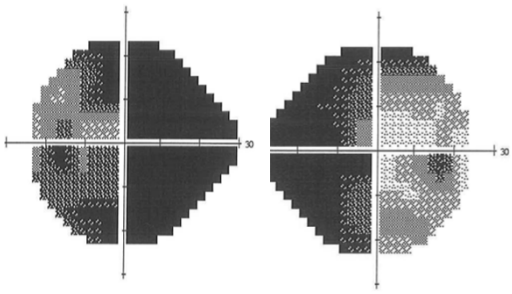

-23.54 db -29.62 db

29

Risk Factors for Poor Visual Prognosis

- Male gender
- African American
- Morbid obesity
- Marked weight
- Obstructive sleep apnea
- Concomitant medications
- Acute onset of signs and symptoms of elevated ICP (fulminant IIH)
- High-grade papilledema
- Lack of headaches
- Lack of ophthalmic oversight

Biousse V. NANOS 2013

30

Gender

- Men represent approx 10% of all IIH
- Less likely to have headache ("estrogen factor")
- Less likely to seek care

Digre & Corbett *Arch Neurol* 1989
Bruce BB, et al. Neurology 2009

31

Race

- No strong influence on development of IIH
- African Americans = more aggressive disease:
  - 3X more likely to have severe vision loss
  - 5X more likely to develop blindness

Bruce BB, et al. *Neurology* 2008

32

Obesity

- NORDIC ave. BMI = 39
- Increased severity of papilledema and visual loss if BMI ≥ 40
- Recent weight gain (5-15%) even in non-obese patients

Szewka AJ, et al. *J Neuroophthalmol* 2013
Wall & George. *Brain* 1991

33

Medications

- Many meds proposed to induce IIH, few test-retest data
- Tetracycline derivatives (minocycline)
- cyclosporine, lithium, nalidixic acid, nitrofurantoin, oral contraceptives, levonorgestrel, danaxol, and tamoxifen

Friedman DI. *Am J Clin Dermatol* 2005
Fraser CL, et al. *Arch Neurol* 2012

34

14 y/o Girl

- HAs x 2-3 weeks
- Rx minocycline x 1 month for acne
- VA: 20/20 OU
- BMI: 23

35

36

37

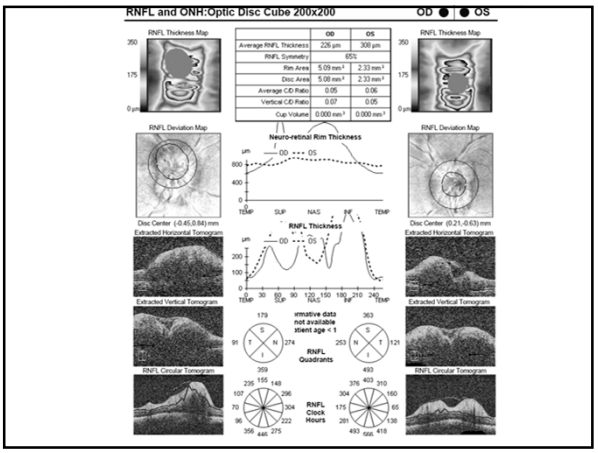

38



39

- **MRI / MRV normal**
- **D/C minocycline**
- **Follow-up x 3 weeks…**

40

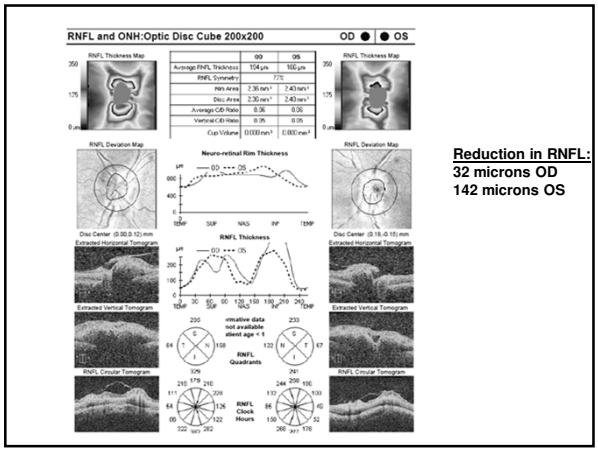

Reduction in RNFL:
32 microns OD
142 microns OS

41

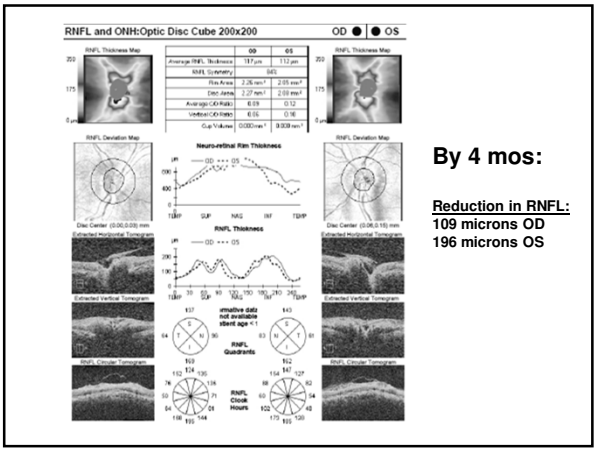

By 4 mos:

Reduction in RNFL:
109 microns OD
196 microns OS

42

Co-Morbidities

- Anemia
- Hypertension
- Obstructive sleep apnea

Biousse V, et al. *Am J Ophthalmol* 2003
Wall M. *Neurol Clin* 2010

43

Other Clinical Findings Predictive of Poor Outcomes

- Absence of headaches
- Severity of papilledema (+/-)
- Marked visual field defects at presentation
- "Fulminant" course (malignant IIH)

Biousse V. NANOS 2013

44

OCT Analysis of Papilledema

- Increased NFL thickness:
  - Nasal > temporal (nasal thickness > 78.0 microns)
- Elevation of nerve head (>0.8 mm from RPE to apex)
- Maintenance of central cup (until late disease)
- Subretinal hyporeflective space between photoreceptor layer and RPE (recumbent "lazy V")
- *Inward deflection of RPE/BM (N>T)*
  - *67% with papilledema*

Flores-Rodriguez P, et al. *Ophthalmic Physiol* 2012
Lee KM, et al. *Ophthalmology* 2011
Kupersmith MJ, et al. *IOVS* 2011

45

32 y/o AA Woman

- C/o progressive headaches am > pm
- BMI: 41
- BVA:
  - 20/20 OD
  - 20/20 OS

46

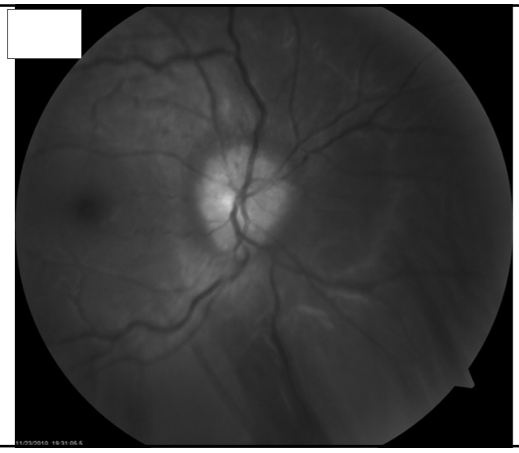

47

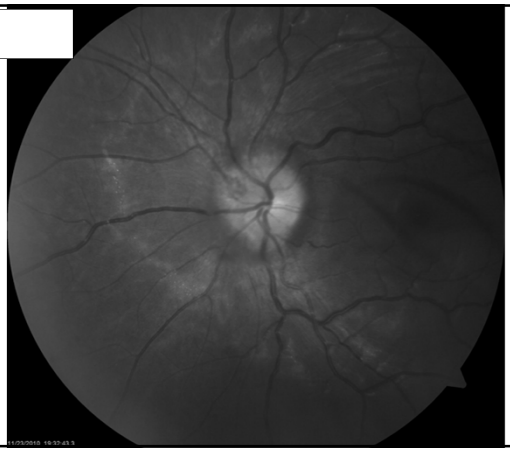

48

49

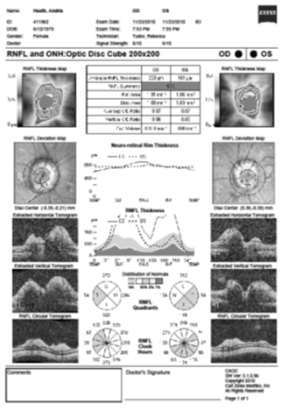

Ave NFL = 228

Ave NFL = 161

50

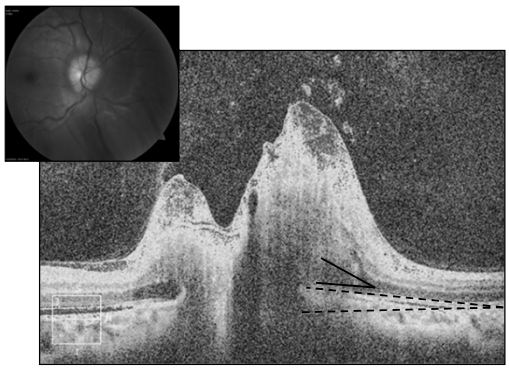

51

37 y/o AA Woman

- C/o chronic daily headaches
- + synchronous pulsatile tinnitus
- BMI: 38
- BVA:
  - 20/20 OD
  - 20/20 OS

52

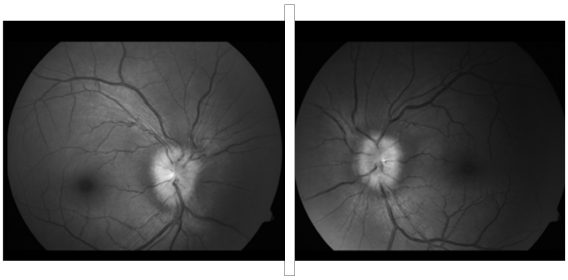

53

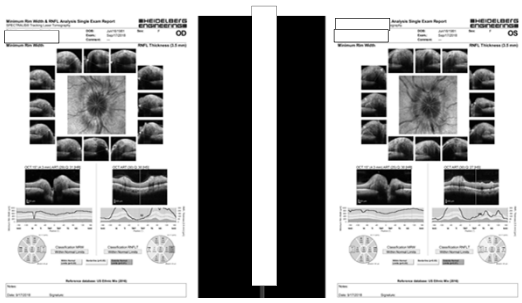

54

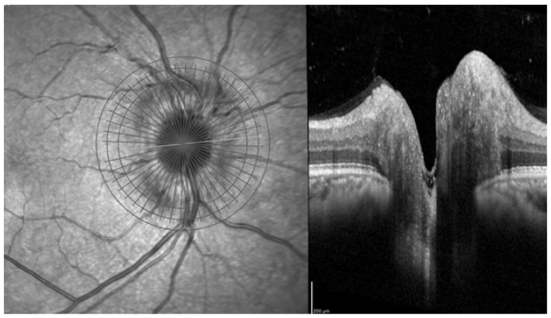

55

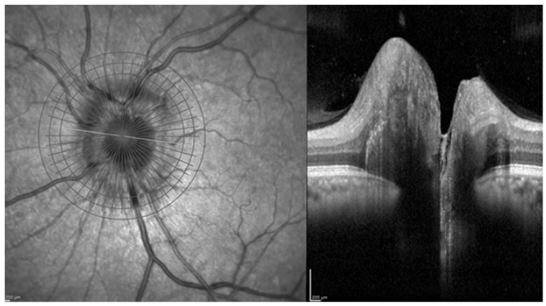

56

40 y/o AA Woman

- C/o chronic daily Has
- + SPT
- BMI = 44
- BVA:
  - 20/40 OD
  - 20/40 OS

57

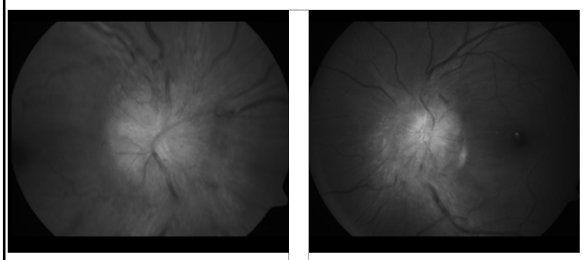

58

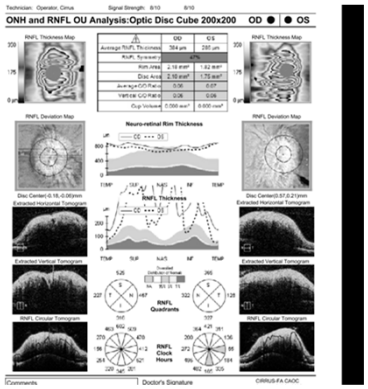

59

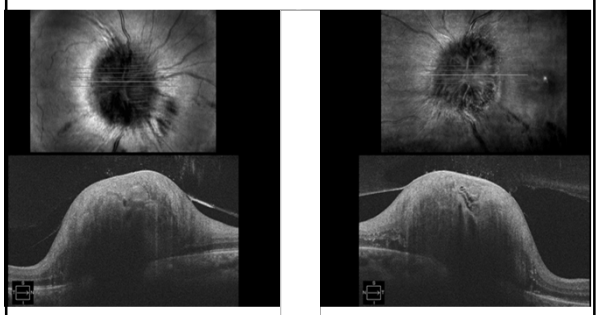

60

38 y/o AA Woman

- Medical history = SLE
- Tx with po prednisone
- Approx. 200 lb weight gain (>400 lbs.)
- BVA:
  - 20/20 OD
  - 20/20 OS

61

62

63



	OD	OS
Average RNFL Thickness	151 µm	186 µm
RNFL Symmetry	93%	
Rim Area	1.74 mm²	1.67 mm²
Disc Area	1.74 mm²	1.60 mm²
Average C/D Ratio	0.07	0.07
Vertical C/D Ratio	0.06	0.06
Cup Volume	0.000 mm³	0.000 mm³

64

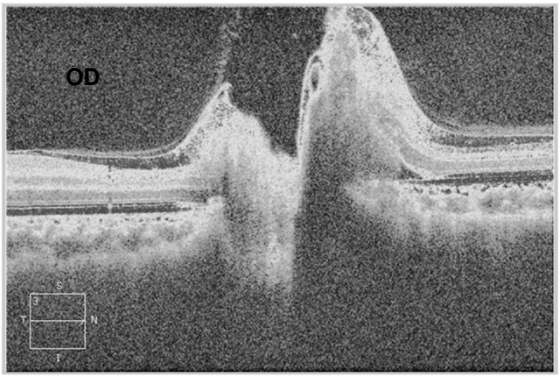

65

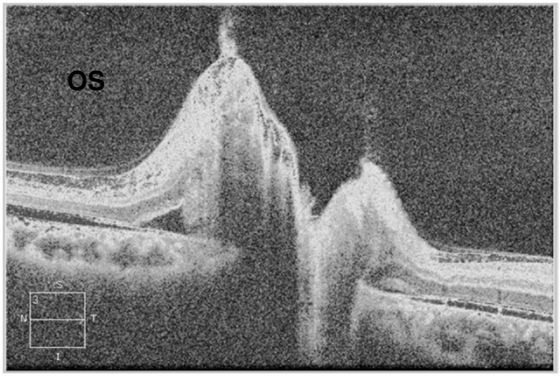

66

Cont.

- MRI / MRV consistent with IIH
- Coordination of care through HMO PCP
  - Nothing done
- F/U @ IEI 5 mos. later complaining of progressive severe HA (10/10)
- BVA:
  - 20/20 OD
  - 20/20 OS

67

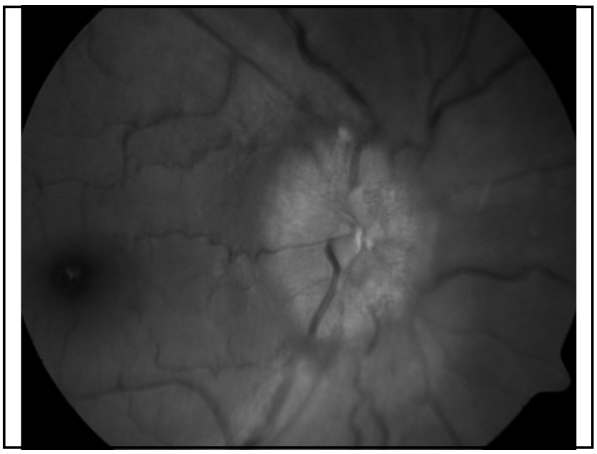

68

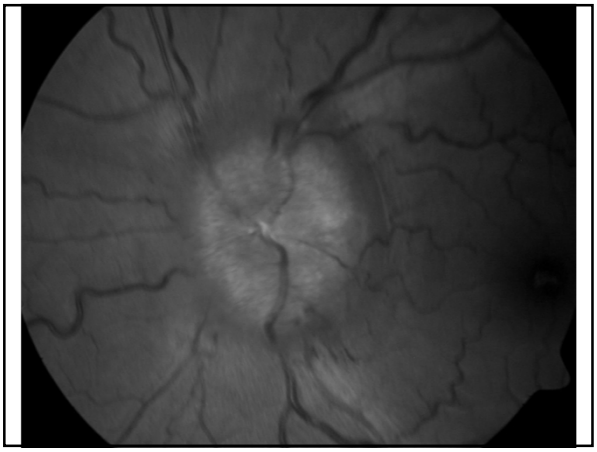

69

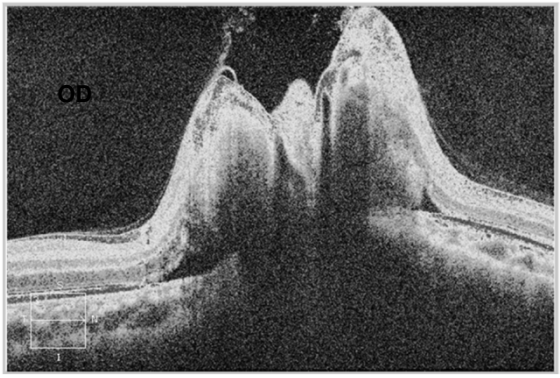

70

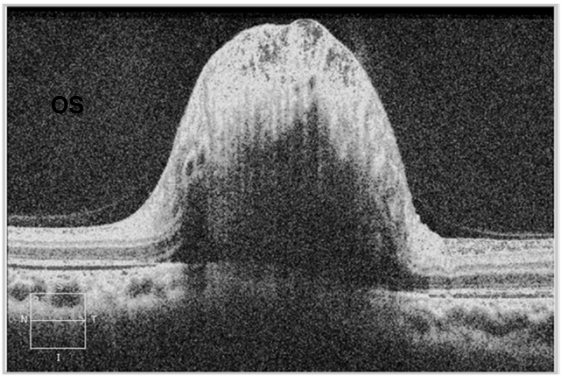

71

Management of IIH

- Observation
- CAI's / diuretics
  - ? value
- Surgery
  - VP shunt
  - ONSF
- Weight loss
  - 5-10% BMI

"Visual Fields"

72

73

NORDIC
IIH Treatment Trial

- Specific Aim 1: The trial is focused on determining the efficacy of low sodium diet with or without acetazolamide to reduce or reverse visual loss.
- Specific Aim 2: (a) To identify proteomic and genetic risk factors for IIH by screening a large cohort of IIH patients and controls.

74

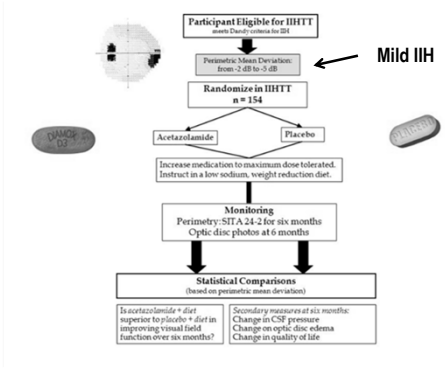

Mild IIH

75

IIHTT 6-Month Results

- Acetazolamide better than diet alone for visual field improvement (PMD reduction of 1.43 vs. 0.71 db)
- Acetazolamide arm showed better weight reduction than diet alone
- Acetazolamide arm showed better resolution of papilledema & improvement of QOL scores vs. diet alone

Wall M, et al. *JAMA Neurol* 2014

76

32 y/o Hispanic Woman

- c/o progressive, debilitating headaches x 2 mos.
- Normal neurologic exam
- BVA:
  - 20/20 OD
  - 20/20 OS
- BMI: 38

77

78

79

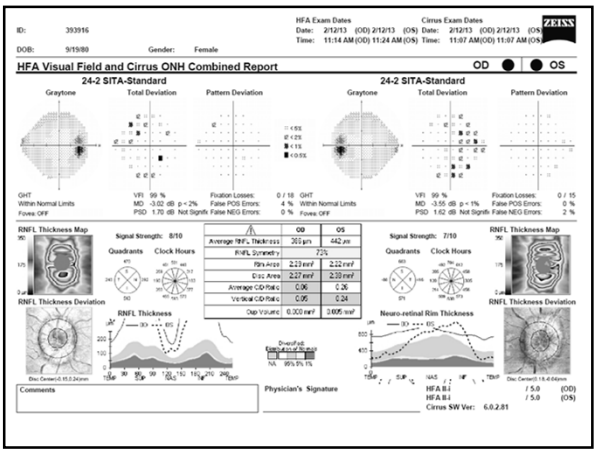

80

81

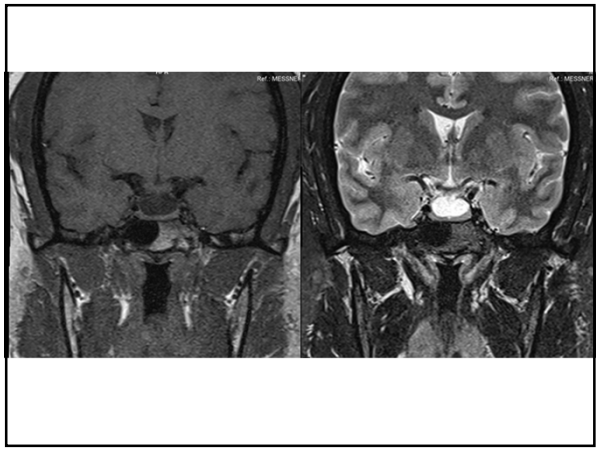

82

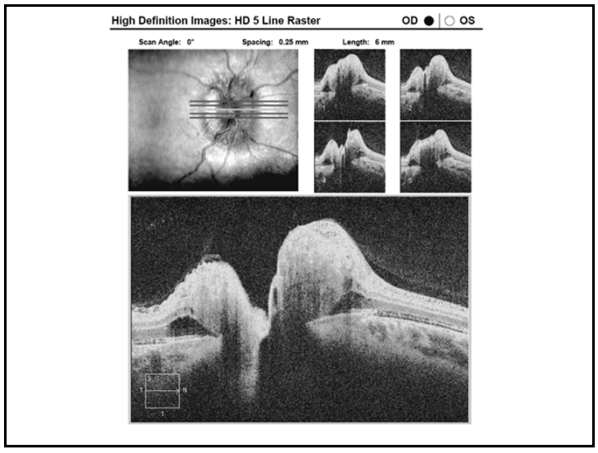

83

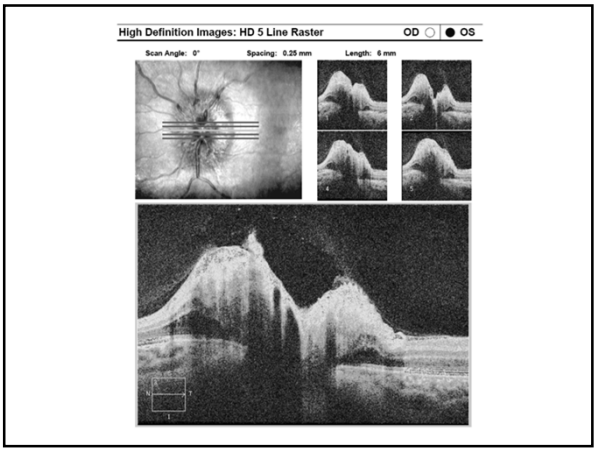

84

F/U x 6 mos

- Rx Diamox (500 mg BID)
- Weight loss (approx. 25 lbs.)
- Improvement in headaches

85

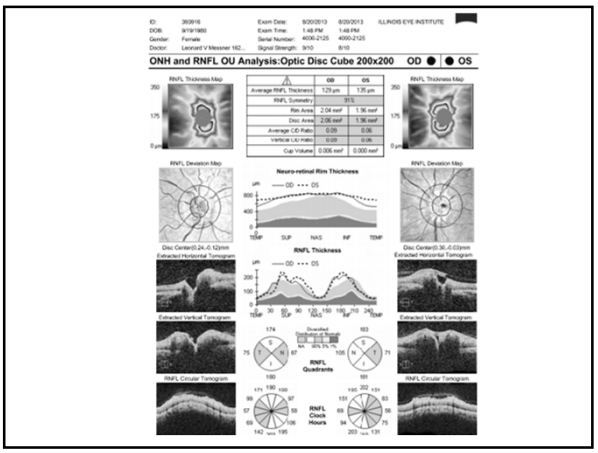

86

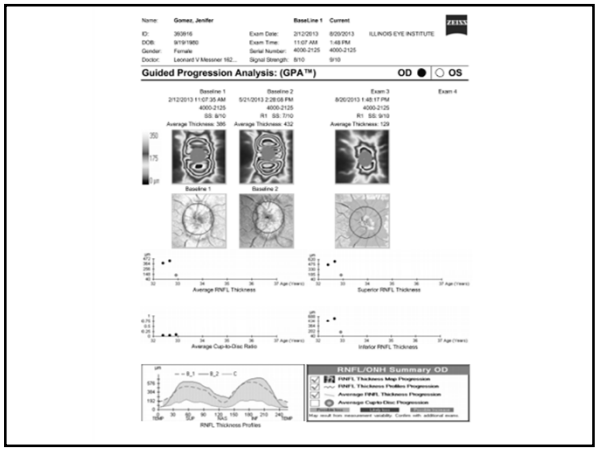

87

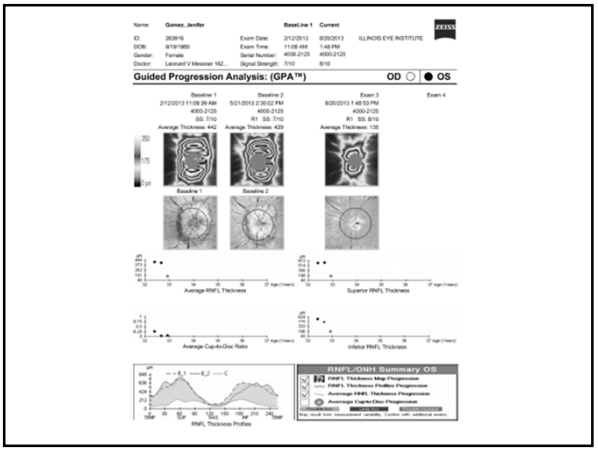

88

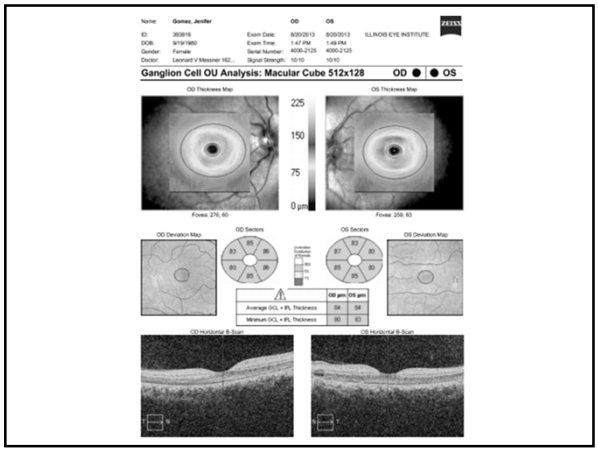

89

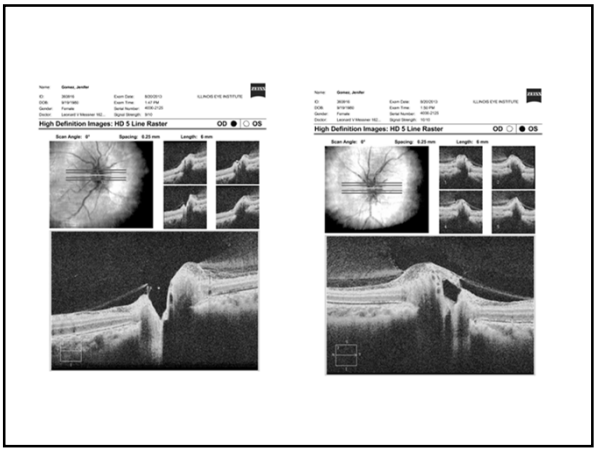

90

F/U x 14 mos

- D/C Diamox x 3 months
- Weight loss (BMI reduction from 38 to 30)
- Headache free

91

92

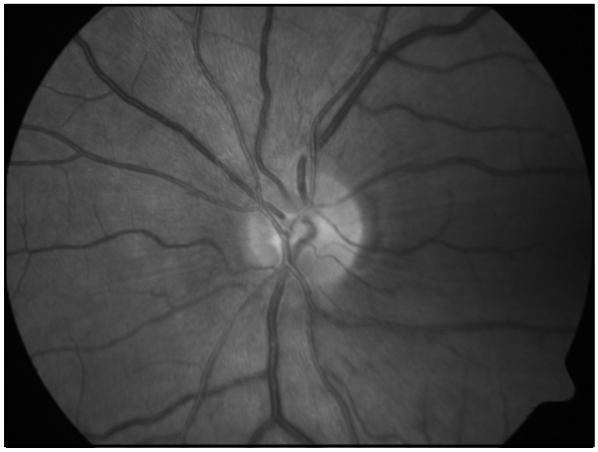

93

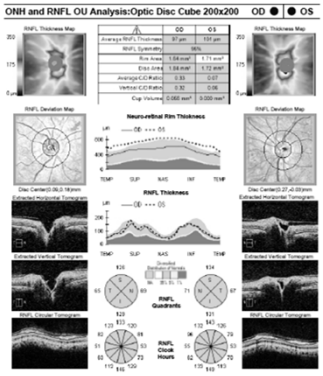

Total RNFL Reduction

OD: 386 to 97
OS: 442 to 101

94

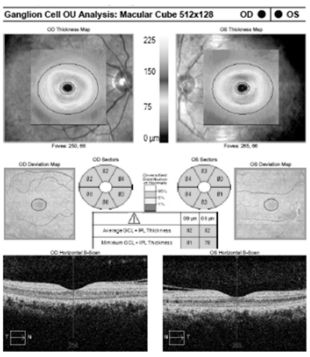

95

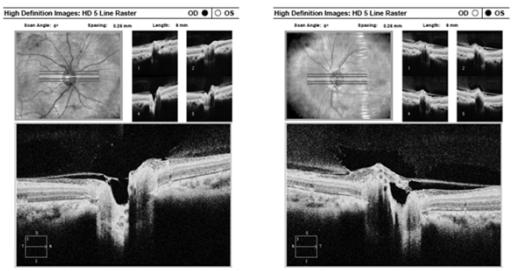

96



97

IIHTT Visual Field Performance Failures

- PF was identified in 21% of participants and in 2.7% of the total number of VF examinations and was reversible on repeat testing
- When perimetric worsening appears to have occurred in someone with papilledema who otherwise is clinically stable or improving, retesting is likely to reveal that the apparent worsening is due to poor performance rather than true worsening of the condition

Cello KE, et al. *J Neuro-ophthalmol* 2016

98

But what if I still have a headache?

99

Headache with IIH

- Most common symptom with IIH (84% in IIHTT)
- 41% with prior history of migraine
- 2/3 persistent HA after remission of IIH (improvement of papilledema)
  - Sensitization of peripheral & central neurons over time

Friedman DI. NANOS 2019

100

IIH - Key Points

- Defining pseudotumor cerebri & IIH
- Pathogenesis of IIH
- Clinical features and neuroradiology
- Prognostic factors and management
- OCT analysis of papilledema
- Visual fields!

101

Thank you!

102