



Conquering the Steep Cornea Contact Lenses in Keratoconus

Melissa Barnett, OD, FAAO

Department of Ophthalmology & Vision Science

University of California, Davis



UC DAVIS

EYE CENTER

Disclosures

Acculens

Alcon

Allergan

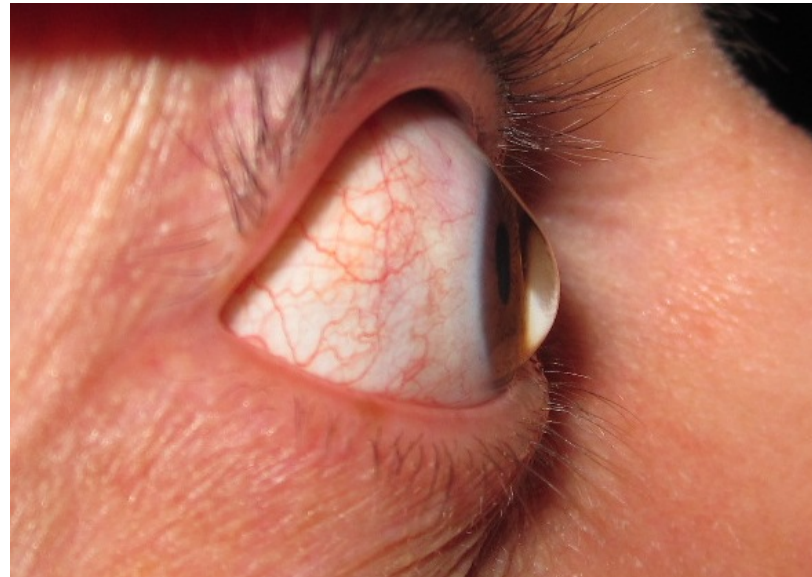
B + L

Nidek

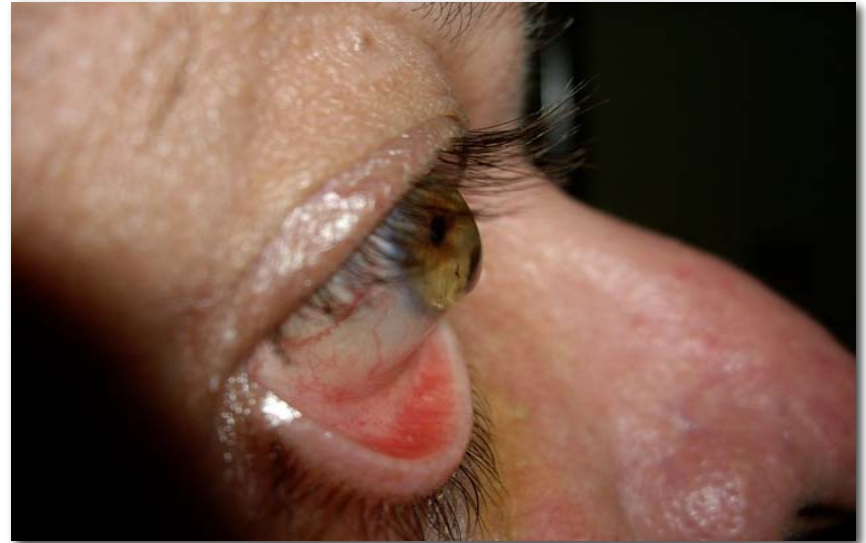SynergEyes

Vistakon

Keratoconus is a non-inflammatory, self-limiting disease of the cornea in which the cornea becomes progressively thinner, more distorted, and steeper in curvature, usually beginning in adolescence.



- Bilateral, asymmetric, non-inflammatory corneal ectasia
- Abnormal curvature causes changes in cornea's refractive power in myopia and astigmatism



NIPPLE



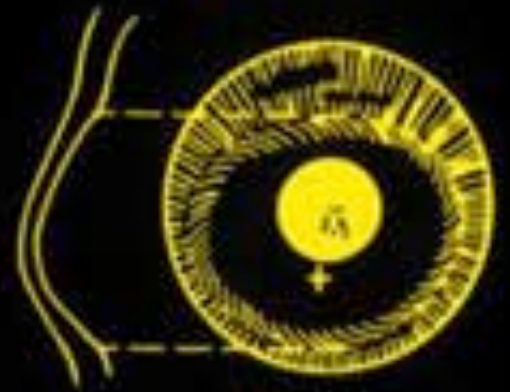A.

OVAL



B.

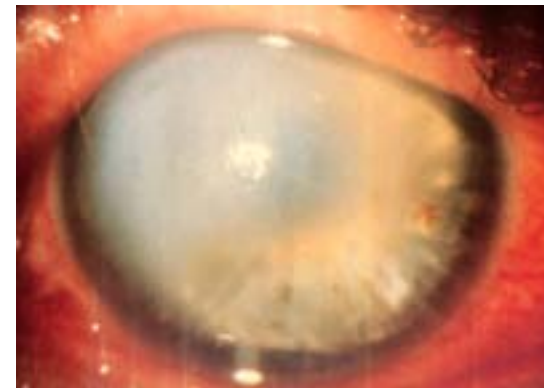
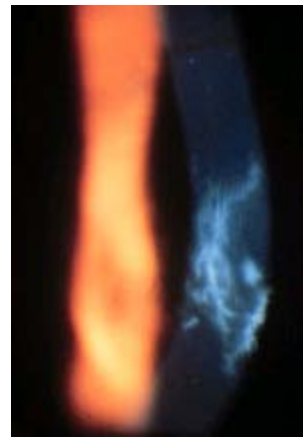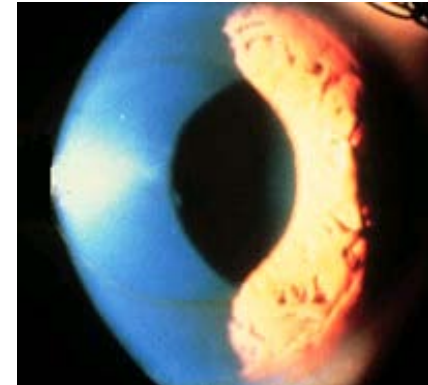
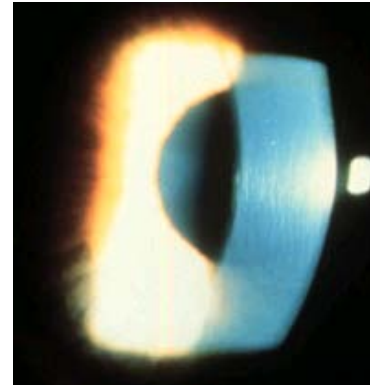
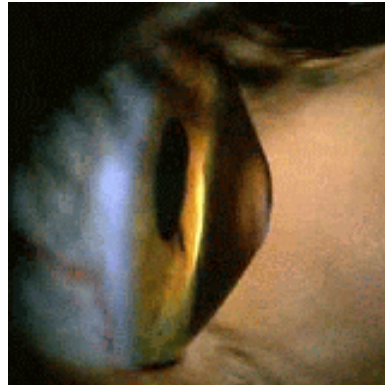
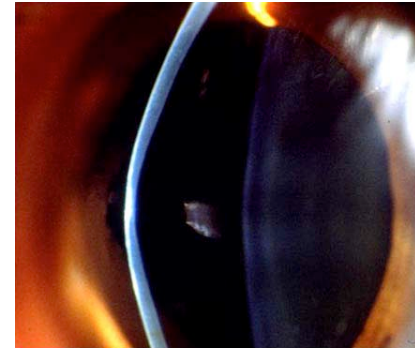
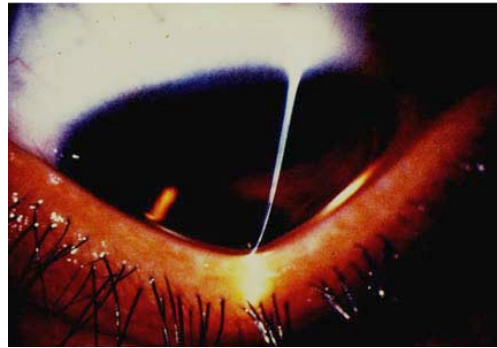
"GLOBUS"



C.

- Prevalence ~ 50 - 230 per 100,000
- Incidence ~ 2 per 100,000
- Onset at puberty
- Progressive until the 3rd or 4th decades of life
- No racial or gender predilection

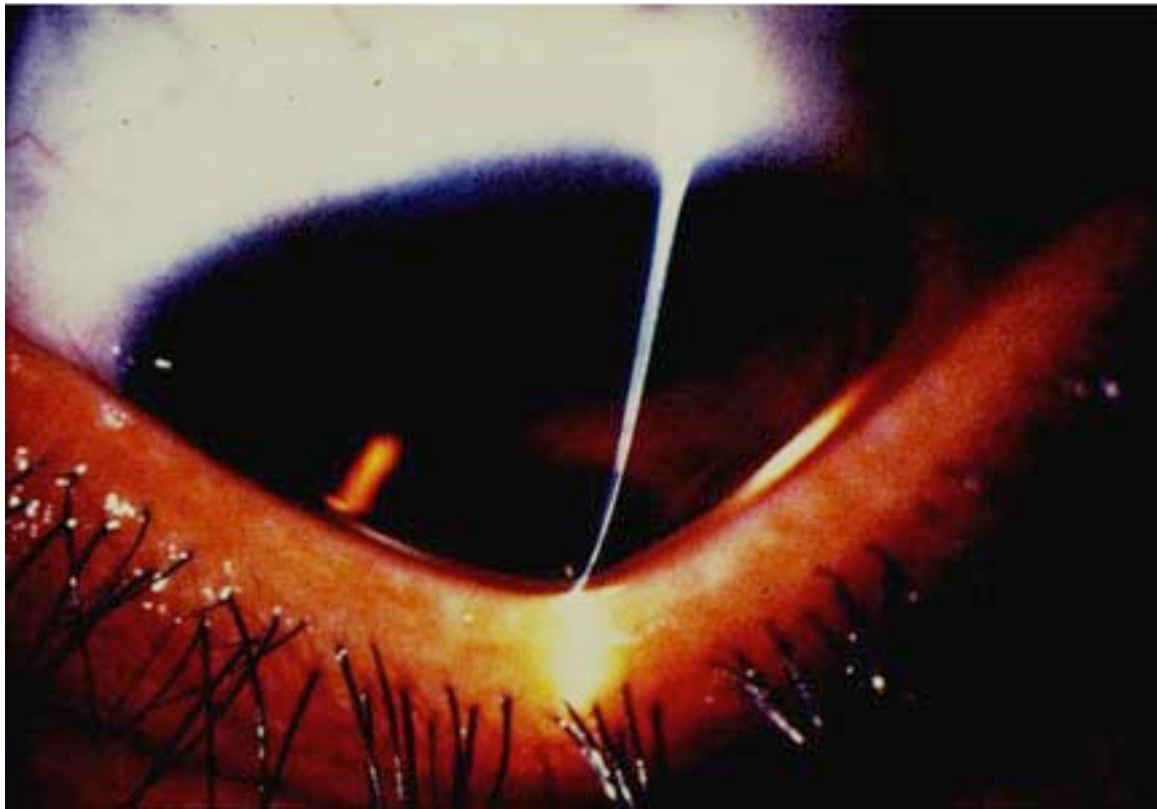Clinical Signs of Keratoconus



- Munson's sign
- Stromal thinning
- Conical protrusion
- Vogt's striae
- Fleischer ring
- Hydrops
- Subepithelial or anterior stromal scars

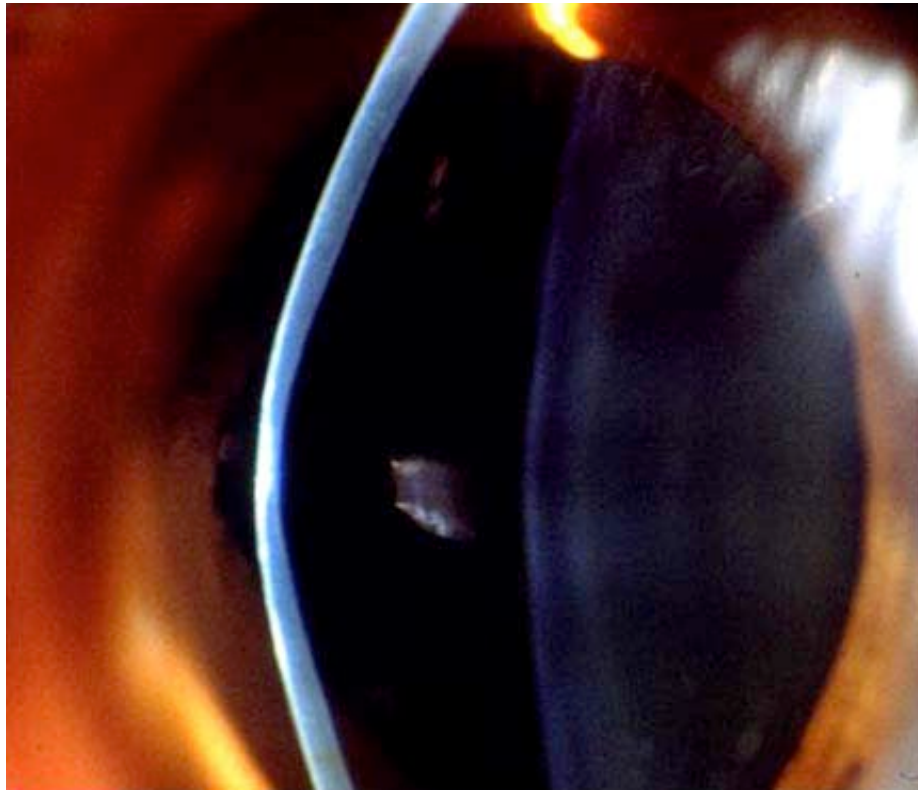
Clinical Signs of Keratoconus

- **Munson's sign**
- V-shaped conformation of the lower lid by the ectatic cornea in downgaze



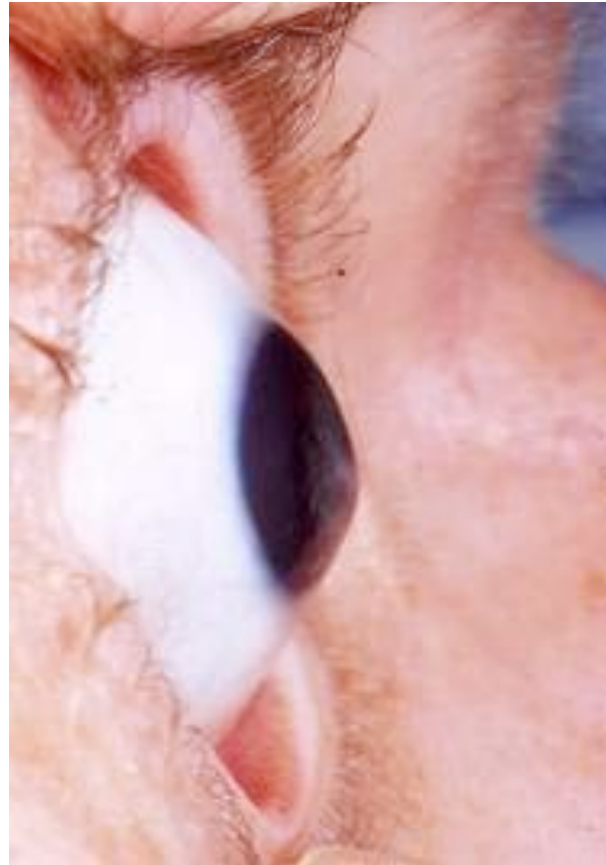Clinical Signs of Keratoconus

- **Stromal thinning**
- Thinning of the stroma
- Most commonly inferiorly or inferotemporally




Clinical Signs of Keratoconus

- **Conical protrusion**



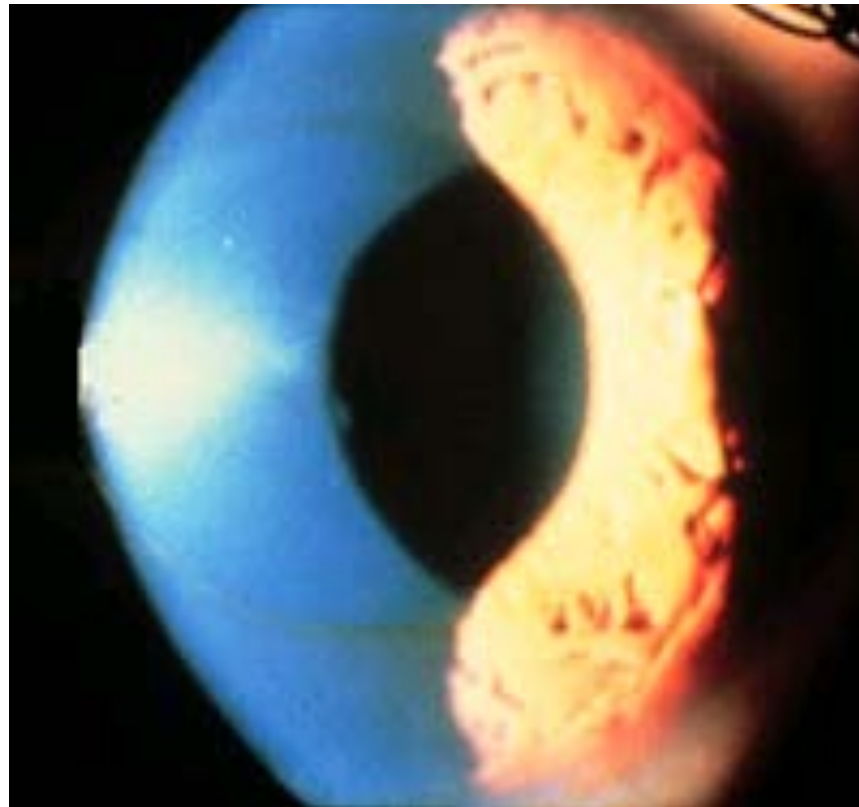
Clinical Signs of Keratoconus

- **Vogt's striae**
- Fine vertical lines in deep stroma and Descemet's membrane



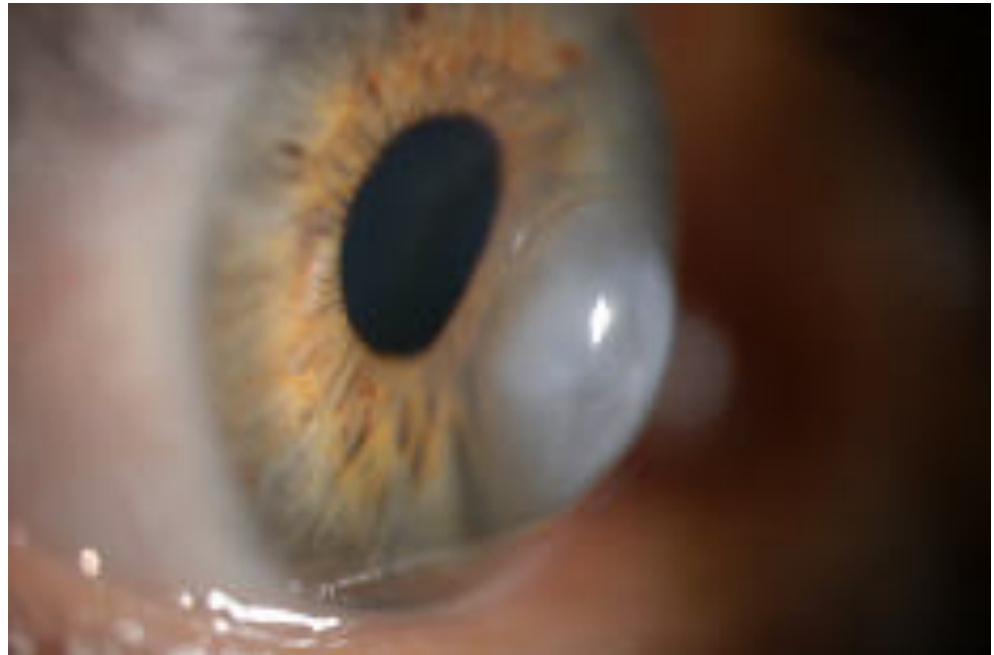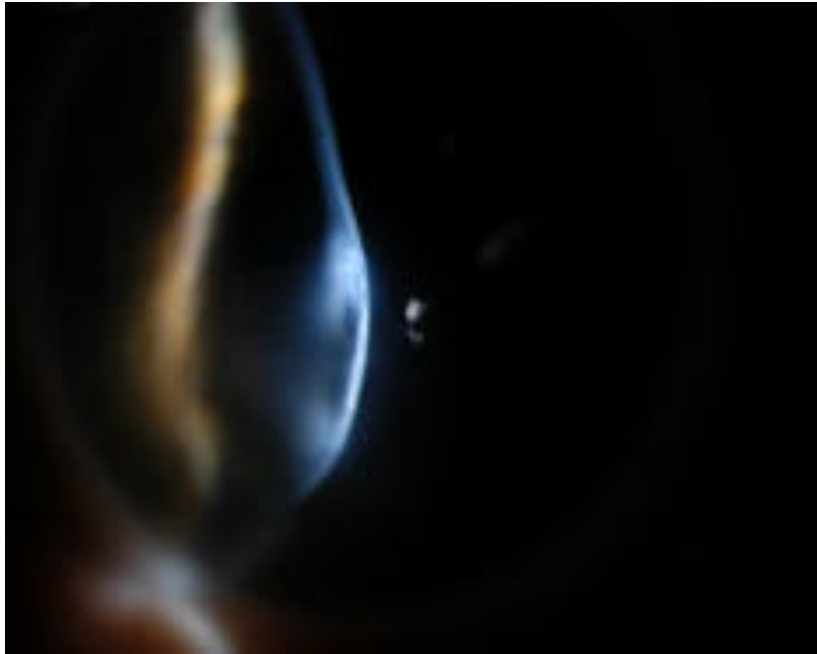
Clinical Signs of Keratoconus

- **Fleischer ring**
- Iron line surrounding the cone partially or completely



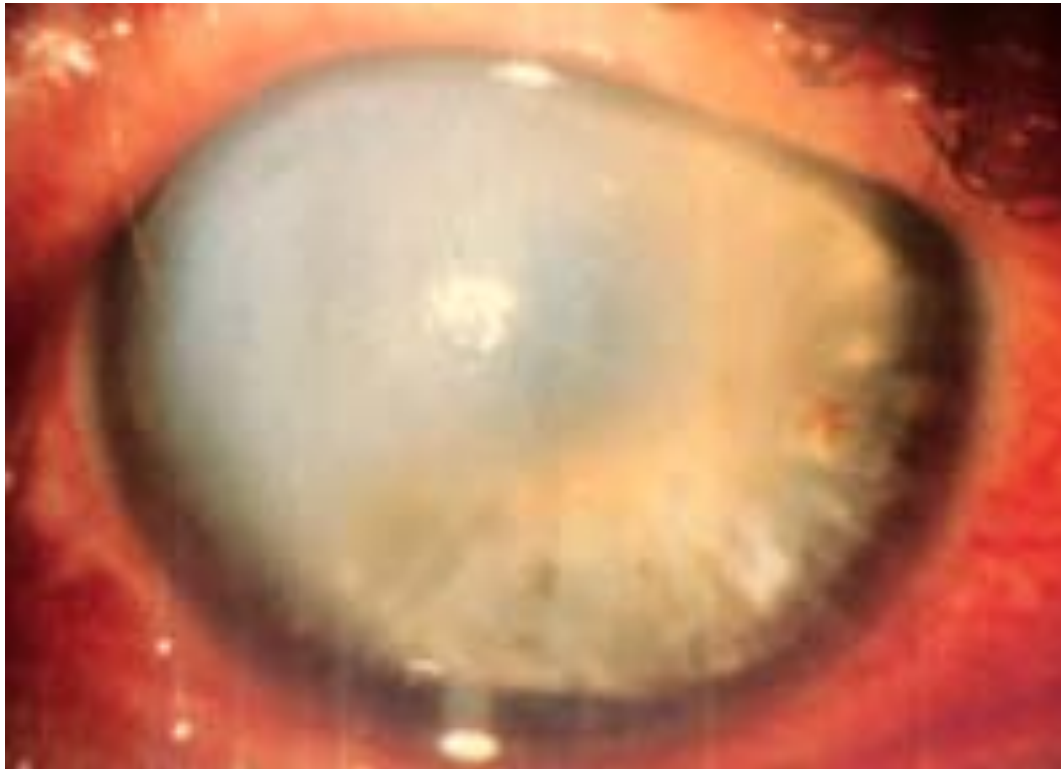
Clinical Signs of Keratoconus

- **Hydrops**
- Breaks in Descemet's membrane



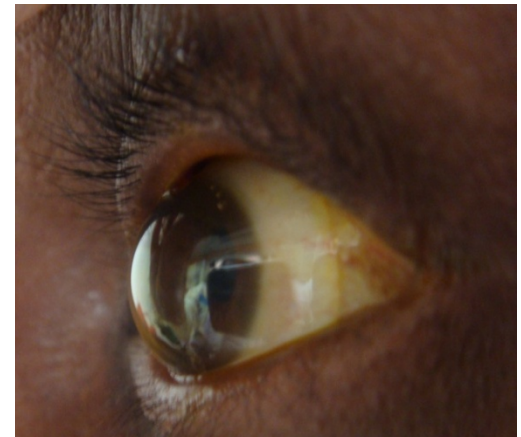
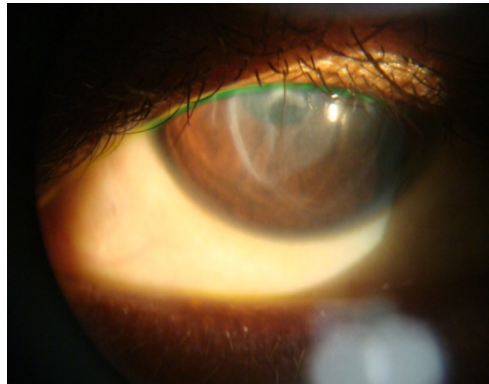
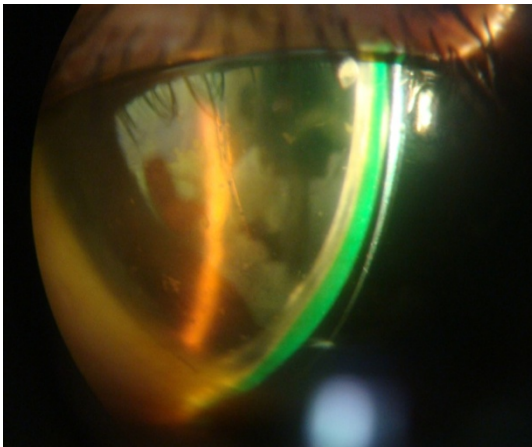
Clinical Signs of Keratoconus

- **Subepithelial or anterior stromal scars**



Hydrops and Mitral Valve Prolapse

- Hydrops affects 5% patients with KCN
- Prevalence of mitral valve prolapse in patients with corneal hydrops due to KCN is 65%

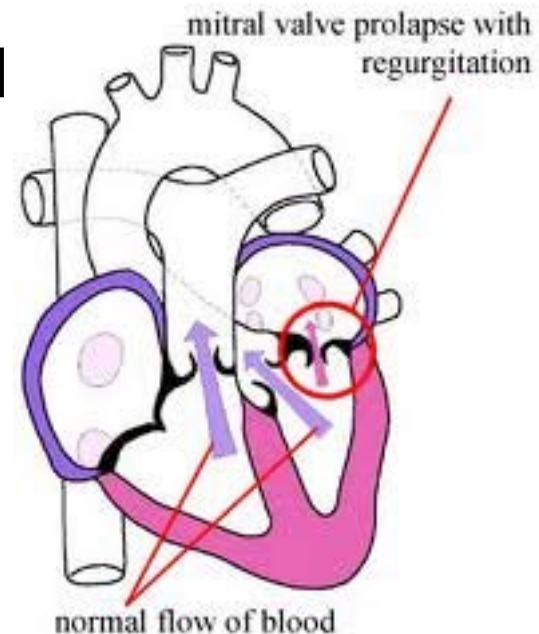


Mindy Toabe, OD

Rabbanikhah, Z. Zahra, M. "Association Between Acute Corneal Hydrops in Patients with Keratoconus and Mitral Valve Prolapse." *Cornea* 2011; 30(2): 154-157.

Mitral Valve Prolapse (MVP)

- Occurs when valve between the heart's left atrium and left ventricle doesn't close properly.
- During MVP, the valve bulges (prolapses) upward, or back into the atrium
- Prevalence 2-3%
- Treatment may or may not be indicated



Keratoconus

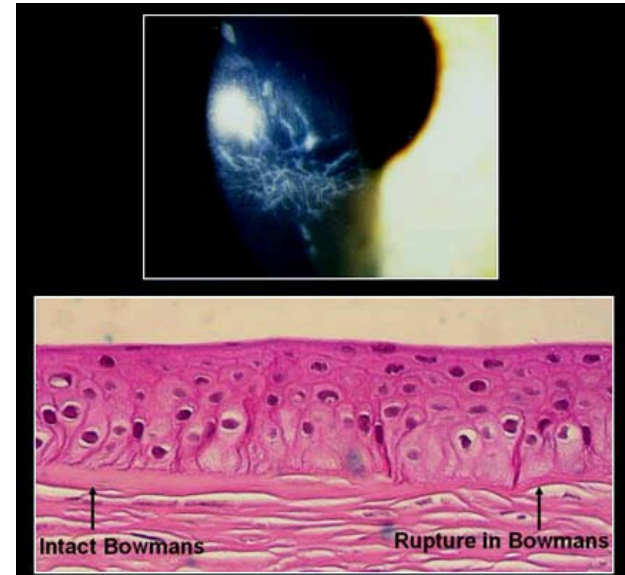
- **Variation in the Lysyl Oxidase (LOX) Gene is associated with keratoconus in family-based and case-control studies.**
- Bykhovskaya Y, Li X, Epifantseva I, et al.
- *Invest Ophthalmol Vis Sci 2012*
- Genome-wide linkage scan in keratoconus families
- Identified a locus at 5q23.2, overlapping the gene coding for the Lysyl Oxidase (LOX)

Keratoconus

- **Variation in the Lysyl Oxidase (LOX) Gene is associated with keratoconus in family-based and case-control studies.**
- LOX encodes an enzyme responsible for collagen cross-linking in a variety of tissues including the cornea.
- Conclusion
- LOX variants lead to increased susceptibility to develop keratoconus.

What is the pathogenesis of Keratoconus?

- Mechanical trauma?
 - Eye rubbing
 - KCN patients eye rubbing 80%
 - normal patients eye rubbing 58%
($p = 0.001$)
- Abnormal structure of Bowmans?
- Abnormal structure of corneal stroma
 - Fewer collagen lamellae?
 - Fewer collagen fibrils per lamella?
 - Abnormal cross-linking of collagen fibrils?

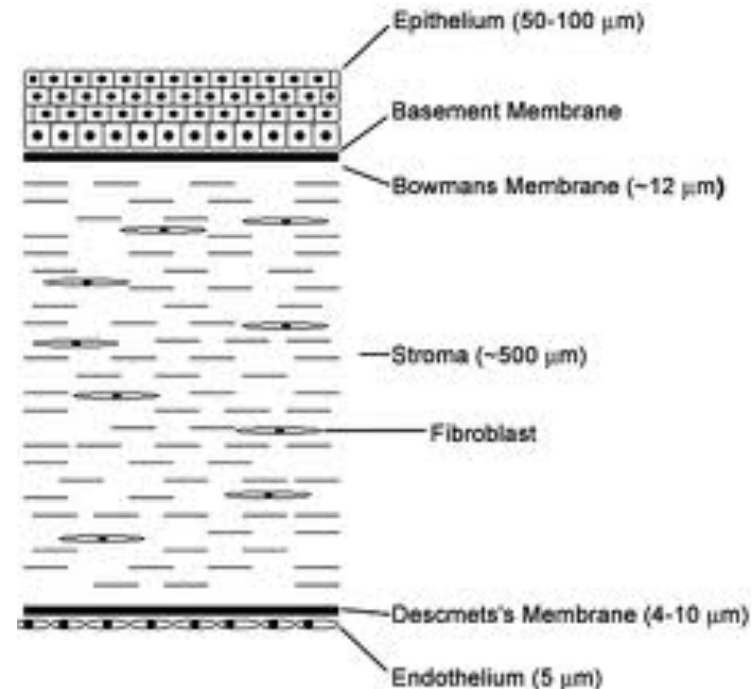


What is the pathogenesis of Keratoconus?

- May be a genetic predisposition that requires a “second hit” or environmental event to elicit progressive disease
- All play a role in KCN
 - genetic factors
 - environmental factors
 - inflammatory mediators

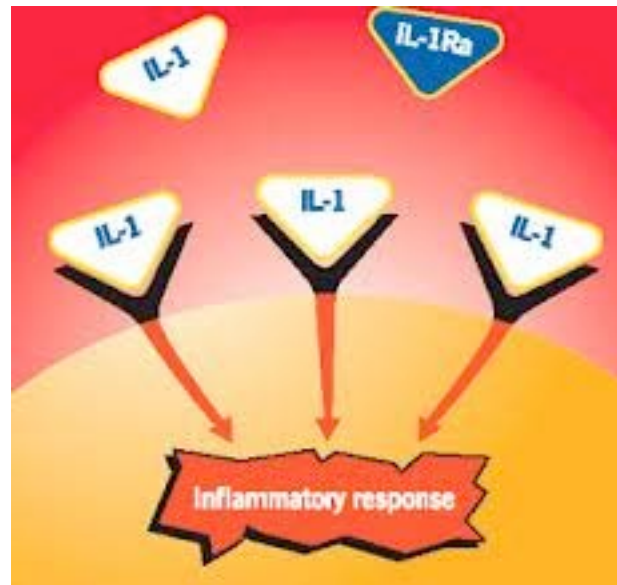Pathogenesis continued

- Increased digestion of corneal stroma
 - Normal collagen composition
 - Increased levels of proteases and catabolic enzymes / decreased levels of proteinase inhibitors



Pathogenesis continued

- Role of interleukin-1 receptors
 - IL-1 induces keratocyte death and negative keratocyte chemotaxis
 - 4-fold increase in IL-1 receptors in keratoconus corneas

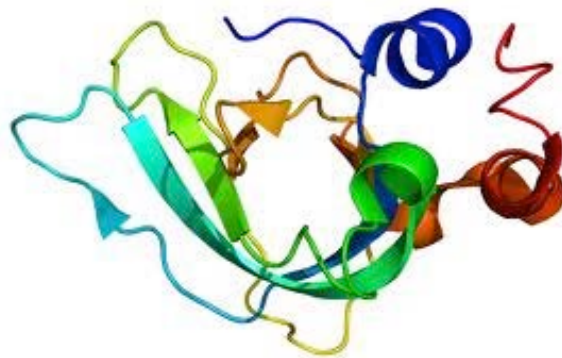

Pathogenesis continued

- Increased expression of matrix-metalloproteinase-1 (MMP-1) in KCN tears
- MMP-1
 - Enzyme that breaks down corneal collagens type I and III
 - May be intermittently expressed, leading to variations in findings

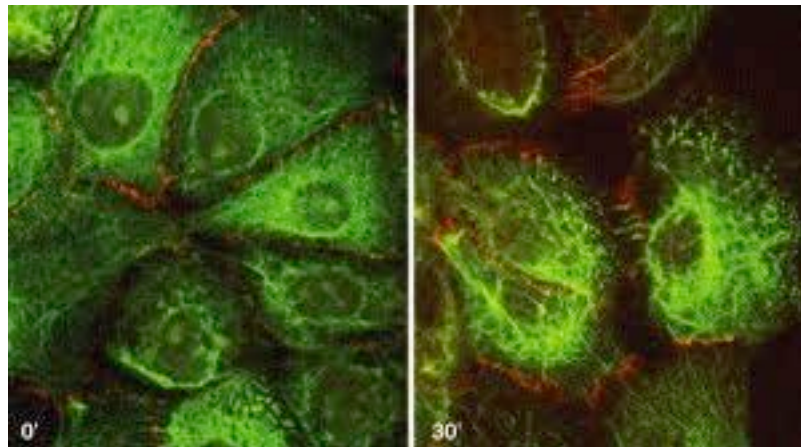
Pathogenesis continued

- Increased expression of tissue inhibitor of metalloproteinase 1 (TIMP-1) in KCN tears
- TIMP-1 and TIMP-2 are underexpressed in clear corneas of early KCN
- TIMP-1 and TIMP-2 may cause scarring in KCN



Pathogenesis continued

- Cytoskeletal keratins
 - Normally found in epidermis but not tears
 - Found in both KCN groups



Factors that Reduce risk of KCN

- Smoking

- Reduced prevalence in KCN patients
- Smoking may increase corneal collagen cross-linking

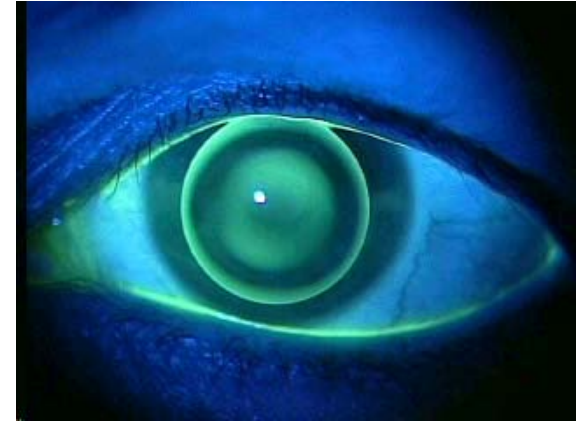


- Diabetes


- Diabetic hyperglycemia may increase corneal collagen cross-linking
- Diabetic patients with KCN have less severe disease

Treatments for Keratoconus

- Contact lenses
- Penetrating Keratoplasty
- Deep Anterior Lamellar Keratoplasty (DALK)
- Intacs - Intrastromal Corneal Rings
- Collagen Cross Linking



- Three-fourths of patients with keratoconus in the developed world will be successfully treated with contact lenses



Evaluation Prior to Contact Lens Fitting

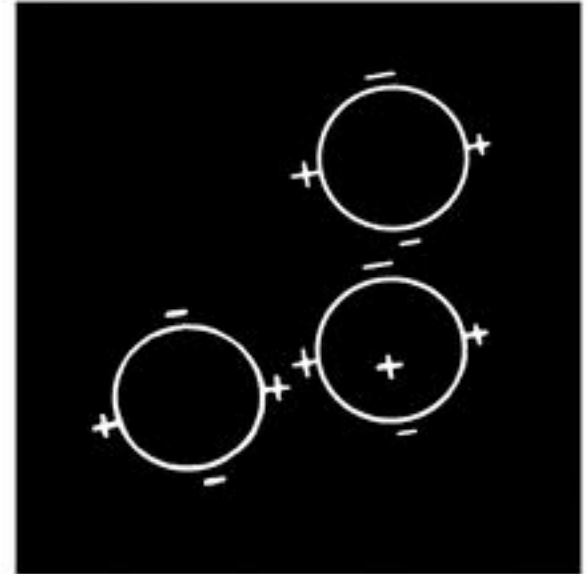
- Verify current lens parameters
 - Base curve
 - Diameter
 - Power
- Evaluate fit of current lenses
- Obtain history of prior lens wear



Evaluation Prior to Contact Lens Fitting

- Keratometry
- Corneal topography
- Subjective refraction

- Anterior segment evaluation
- Ocular surface quality



Carrie

- 31 year old female
- Resident physician

- Entering VA (with CLs)
- OD 20/30
- OS 20/25

- OD - faint Fleisher ring inferior, central corneal thinning
- OS - very faint Fleisher ring inferior, central corneal thinning

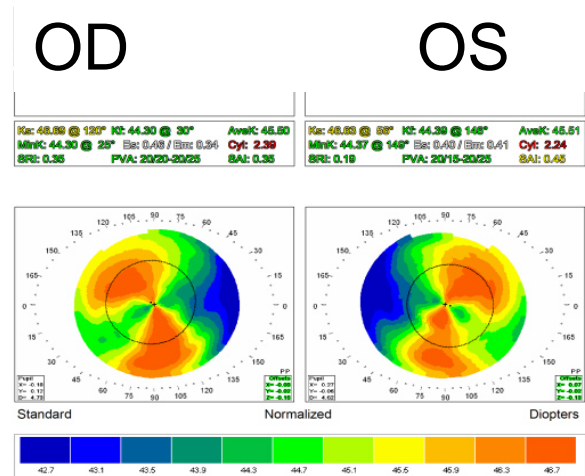
Carrie

- sim Ks

OD 46.49 @ 130 / 44.30 @ 030

OS 46.63 @ 056 / 44.38 @ 146

- h/o KCN with atypical topography for KCN, but likely KCN given thinning of cornea OU (476 / 471)



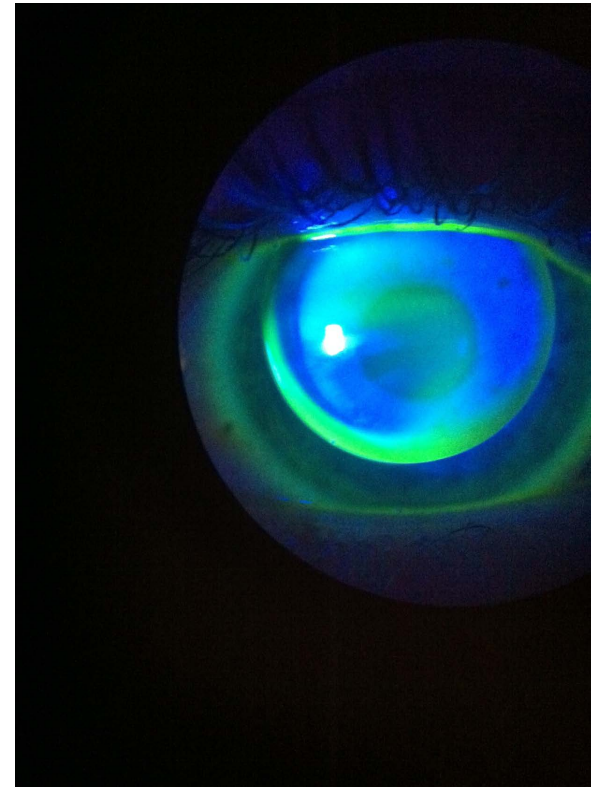
Carrie

new contact lens fitting Kone design

- OD 45.62 (7.40) / -3.25 / 9.5 G
- OS 46.00 (7.34) / -3.25 / 9.2 B

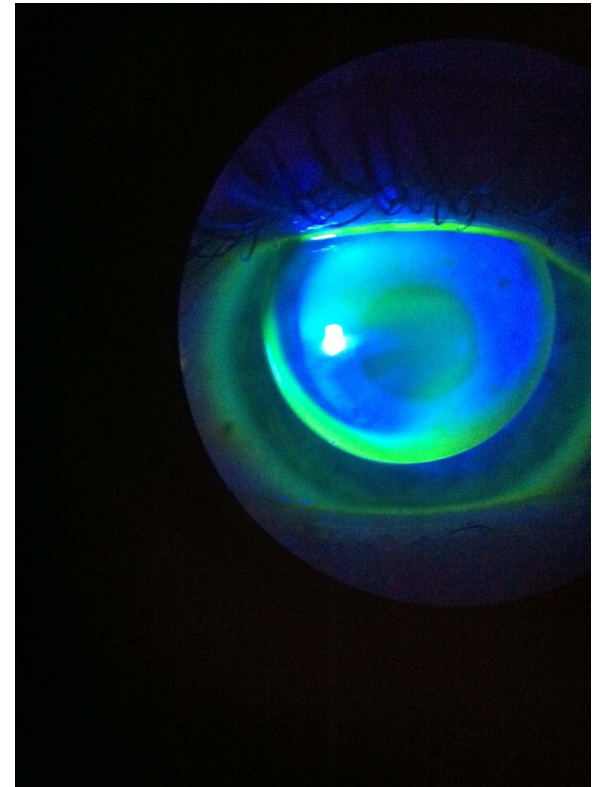
- Follow up
 - Good vision and comfort
 - Able to wear lenses all day, not all night

- OD 20/25+2
- OS 20/20



Carrie

- Two years later...
- Good vision and comfort
- OD 20/25+2
- OS 20/20



Indications for a Small Diameter Gas Permeable Contact Lens

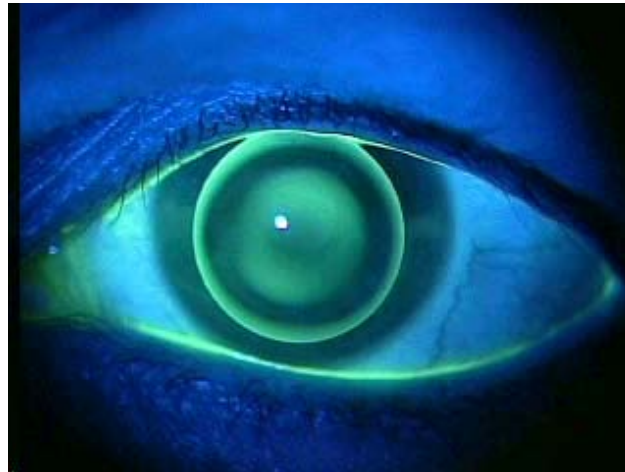- Normal corneas
- Regular astigmatism
- Irregular astigmatism that is focal, symmetric or centered
 - Small, central cones
 - Mild cones

Small diameter GP lenses (8.0 – 10.0 mm diameter)

- Custom parameters
- CLEK diagnostic set
- Rose K (Blanchard) GP lenses
(aspheric base curve)
- Reverse Geometry designs

Fitting goals

- Minimally vault over corneal apex
- Mid-peripheral bearing
- Moderate peripheral clearance
- Lens centration over the cone



Rose K ideal fit

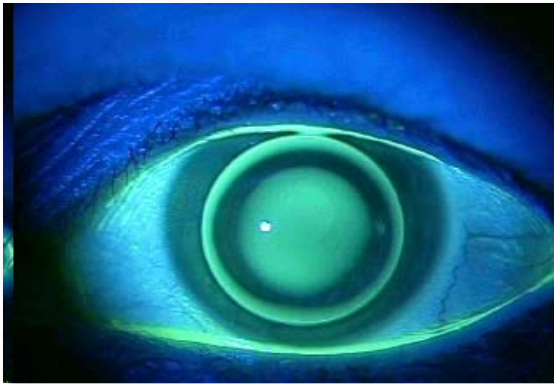
Advantages

- Provide smooth, regular surface that masks underlying corneal irregularity
- Good tear exchange

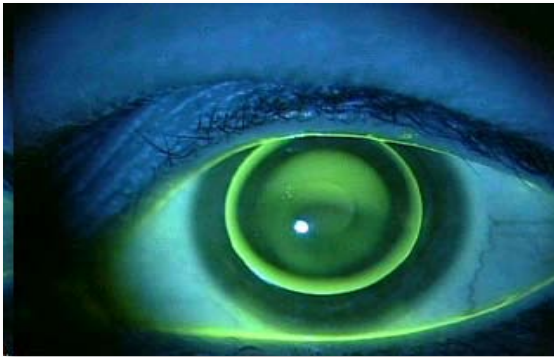Disadvantages

- Least stable (more likely to decenter)
- Most difficult for patient adaptation
- Poor comfort - GP intolerance

Rose K2: Central Fit



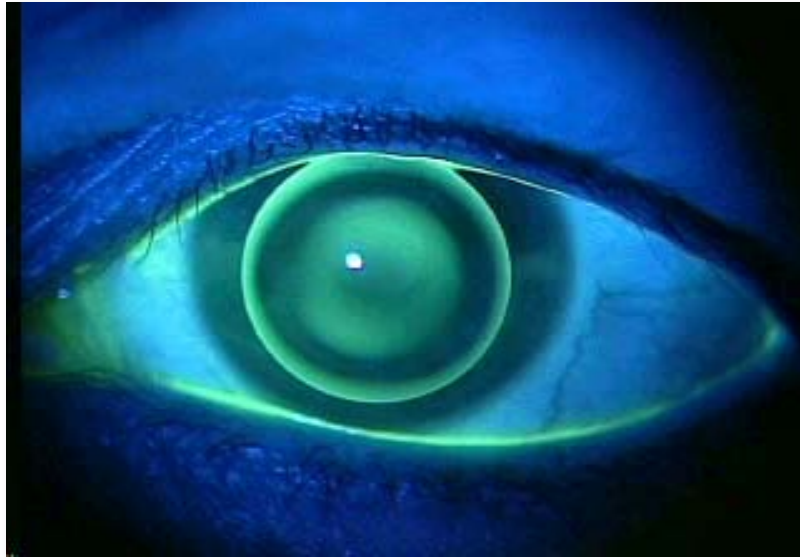
- Start steep



- Go flat

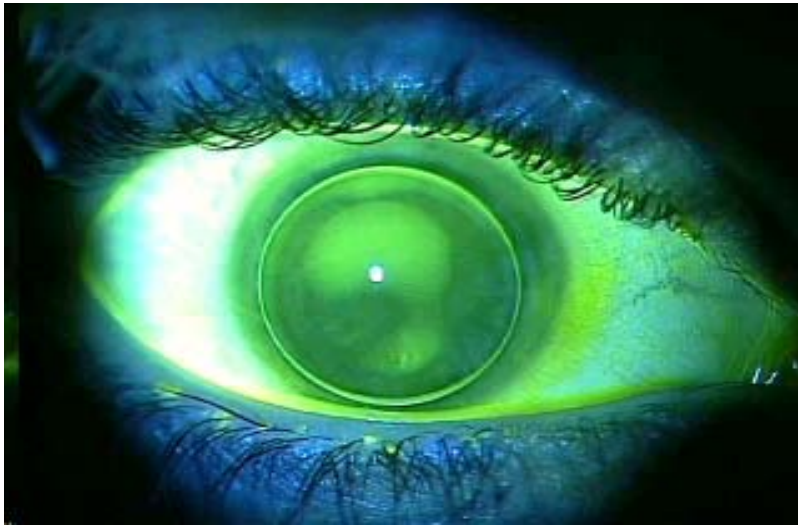
pictures courtesy of Lee Buffalo,
Blanchard Contact Lens, Inc.

Rose K2



- Ideal fit
 - Light feather touch

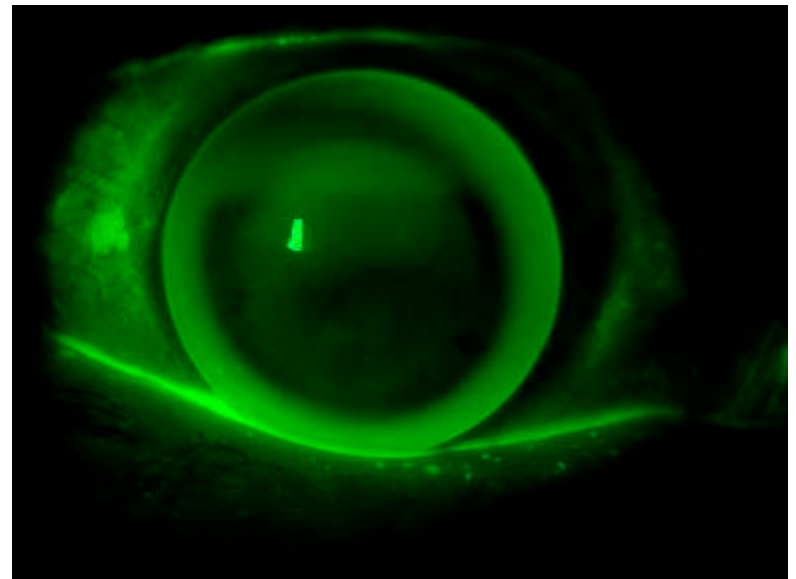
pictures courtesy of Lee Buffalo,
Blanchard Contact Lens, Inc.



Too tight, go flatter

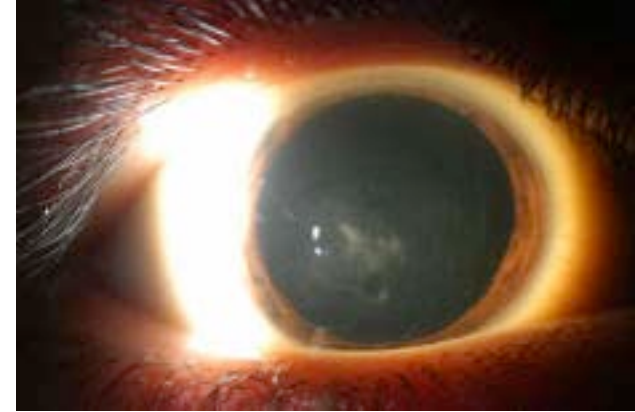
Peripheral curves

Too loose, go tighter



Steve

- 57 year old Caucasian male
- Entering VA (with CLs)
- OD 20/50 SOR +2.50 20/25+2
- OS 20/25 SOR +0.50 20/25
- Cornea
 - OD - inferior central apical scarring, central thinning
 - OS - inferior central scarring
- Lens
 - 2+ nuclear sclerosis, 1+ cortical cataract OU



Steve

- Medical history – diabetes, hypercholesterolemia, erectile dysfunction, keratoconus, glaucoma suspect
- Family history – no significant history
- Social history – office worker
- Ocular Medications – none
- Systemic Medications – glucosamine HCL, sildenafil, fosinopril, metformin, metoprolol, pravastatin, warfarin

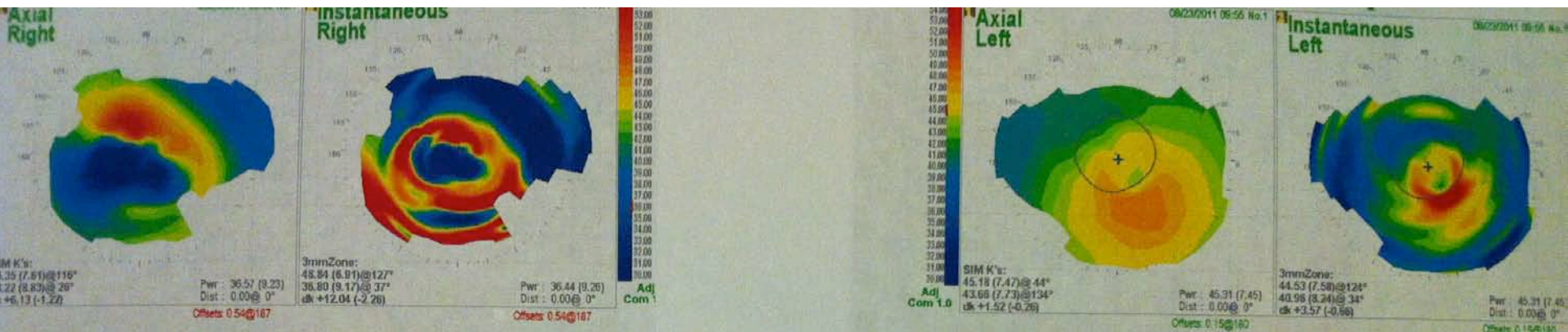
Steve

- Optic nerves
OD 0.65 / 0.65
OS 0.50 / 0.45
- Macula
OD normal
OS trace hard drusen

Steve

- sim Ks
OD 50.15 @ 134 / 47.87 @ 044
OS 44.53 @ 047 / 43.05 @ 137

OD central and superior steepening
OS inferior steepening



Steve

Current gas permeable lenses

- OD 7.00 / -10.75 / 8.7
- OS 7.60 / -5.75 / 9.0

- Vision could be better
- Good comfort

- Fit
 - OD
 - Interpalpebral
 - Inferior decentered
 - Alignment
 - Thin peripheral systems
 - 1+ scratches on lens surface

- OS
- Interpalpebral
- Centered
- Alignment
- Good peripheral systems
- 1+ scratches on lens surface

Steve

Impression

- No evidence of diabetic retinopathy in either eye.
 - Keratoconus with scarring OD > OS.
 - Glaucoma suspect.
 - Fit and vision could be improved with gas permeable contact lenses.
-
- Plan
 - Good diabetic control.
 - Corneal topography done.
 - Visual field and optic nerve photographs scheduled.
 - Gas permeable contact lens refit.

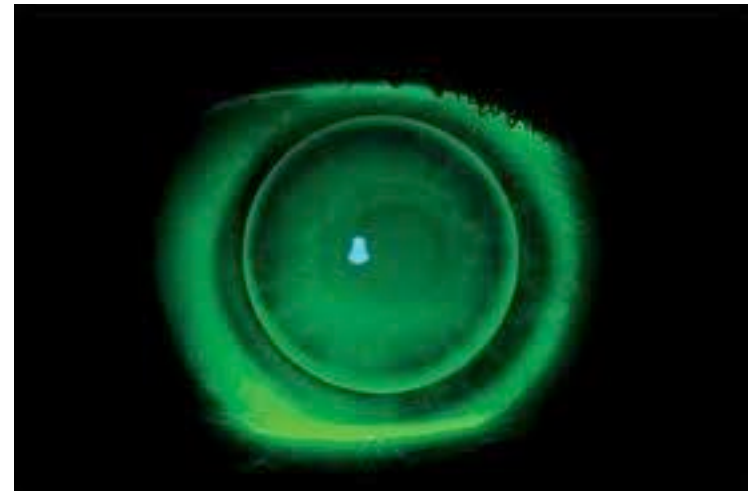
Steve

New gas permeable lenses ordered

- OD 49.00 / -9.12 / 9.0 / 8.50x.4 / 10.8x.4 / 7.0 OZ blue
- OS 49.00 / -5.25 / 9.0 / 8.50x.4 / 10.8x.4 / 7.0 OZ blue

Steve

- With new lenses
- VA
OD 20/20 SOR pl
OS 20/20-2 SOR pl
- Fit
OU
Interpalpebral
Centered
Alignment
Good peripheral systems
Clean lens surface



Steve

- Two years later...
- Retains good vision and comfort
- OD 20/20+2
- OS 20/20-2
- Stable fit of lenses

Intra-Limbal Lenses

- Slightly smaller than the cornea
- 10.5 mm - 12 mm diameter
- Adult cornea
 - Horizontal diameter 11.5 - 12.6 mm
 - Vertical diameter 10.5 - 11.7 mm

The Intra-limbal Lens: Indications

- Irregular corneas
- Poor centration, stability and / or comfort with smaller RGP lens diameters
- RGP lens intolerance with smaller RGP lens diameters
- Soft lens intolerance due to large amounts of astigmatism or neovascularization

Intra-limbal Lenses: Indications

- Large cones
- Decentered keratoconus
- Pellucid marginal degeneration

Intra-limbal Lenses (10.5 mm - 12 mm diameter)

- DynaZ Intralimbal 11.2mm
 - Lens Dynamics
- KBA 10.2mm
 - Precision Technology Services
- Rose-K2 IC 11.2mm
 - Blanchard CL

Intra-limbal Lenses (10.5 mm - 12 mm diameter)

- XL-T 11.0 - 12.0mm
 - Visionary Optics Innovations
- GBL 11.2 mm
 - ABB - Concise
- I Kone 10.4 mm
 - Visionary Optics and Valley Contax

Fitting Goals

- Central corneal vault or light feather touch
- Mid-peripheral bearing with moderate peripheral clearance
- Movement (less than traditional RGP) and should provide adequate tear exchange

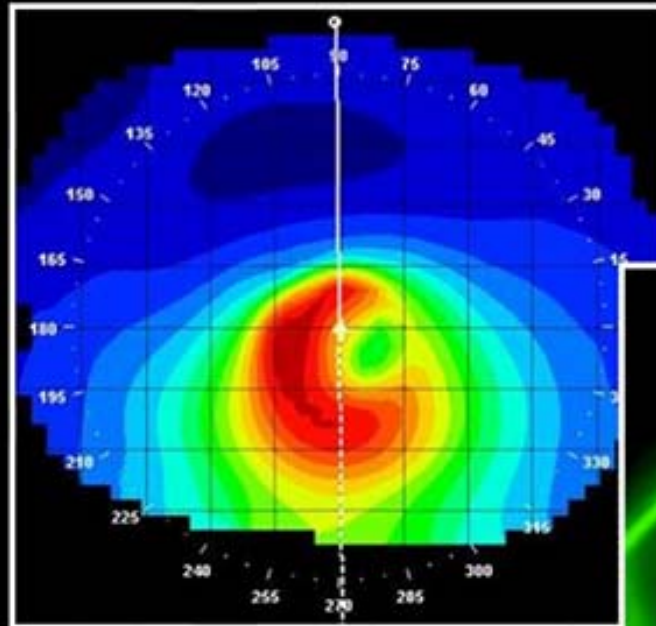
I Kone

- Bi-surface aspheric design
- Diameter 9.6mm
 - Also available in 8.8mm and 10.4mm
- Aspheric anterior surface
 - Reduce spherical aberrations

I Kone

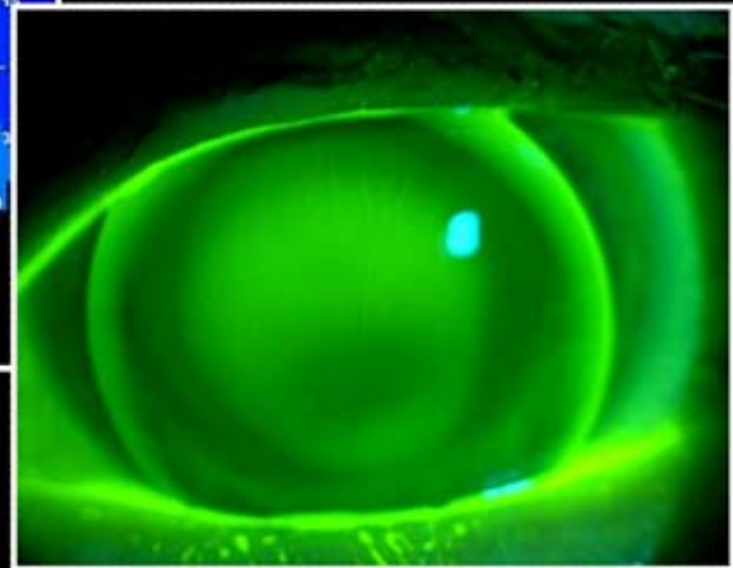
- Four conic zones on posterior surface
 - Central area vaults cornea to reduce corneal scarring
 - First and second zones distribute pressure over larger area to manage corneal ectasia
 - Peripheral curve, composed of third and fourth zones, provides an alignment fit over non-ectatic area of cornea

I-Kone Fitting Goals

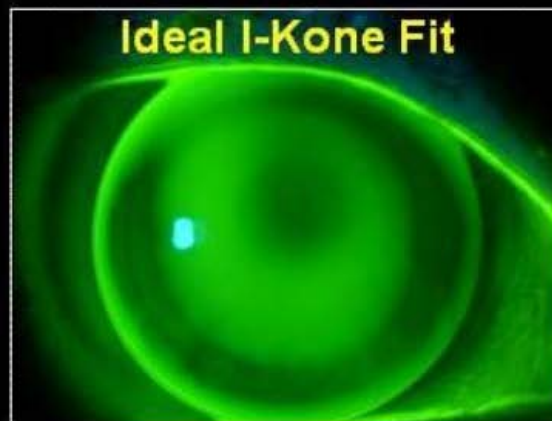
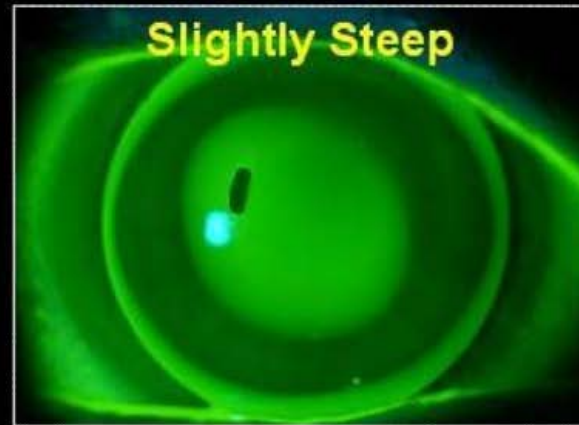
Apical clearance or
slight feather touch

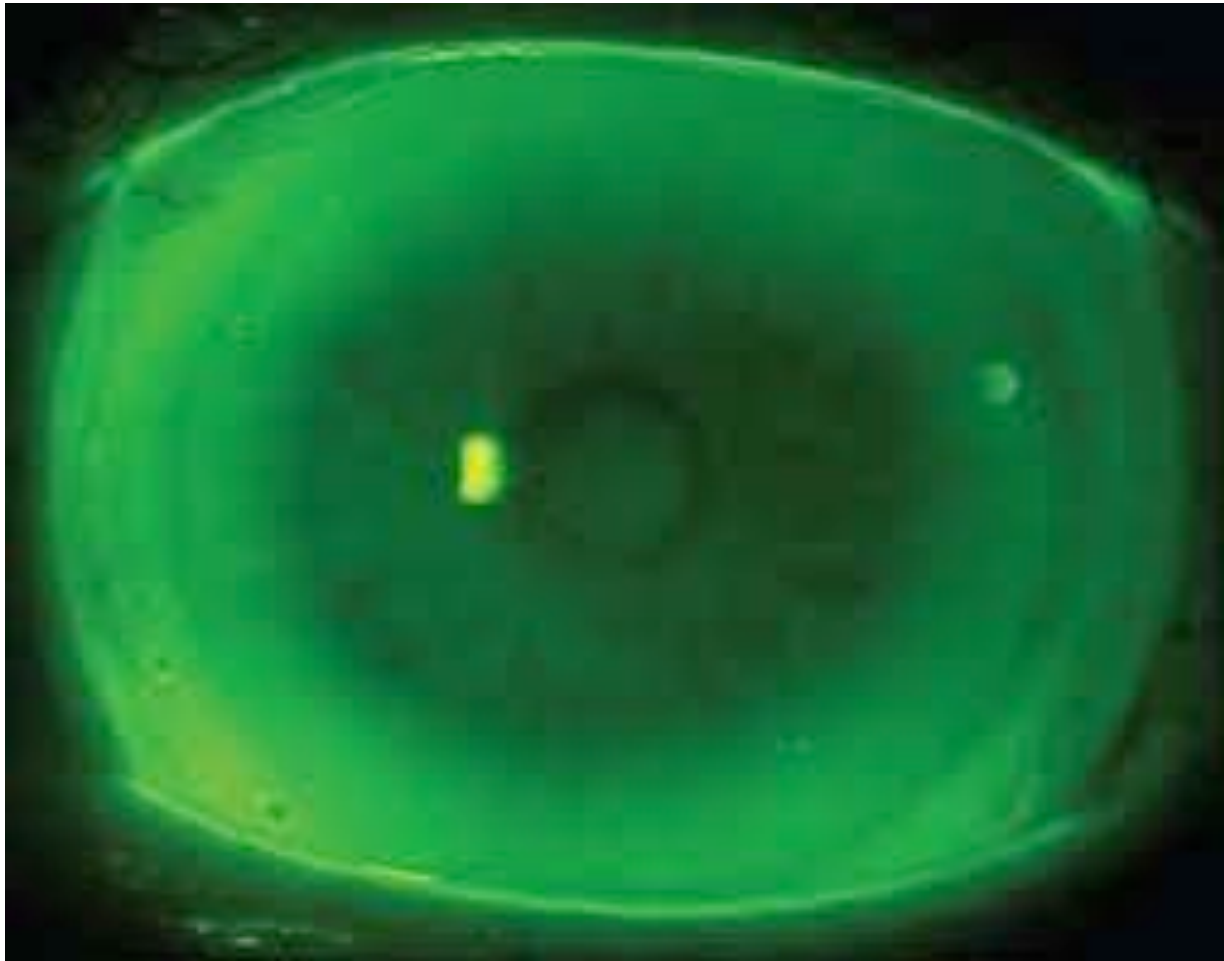
Alignment in the more
normal peripheral
cornea



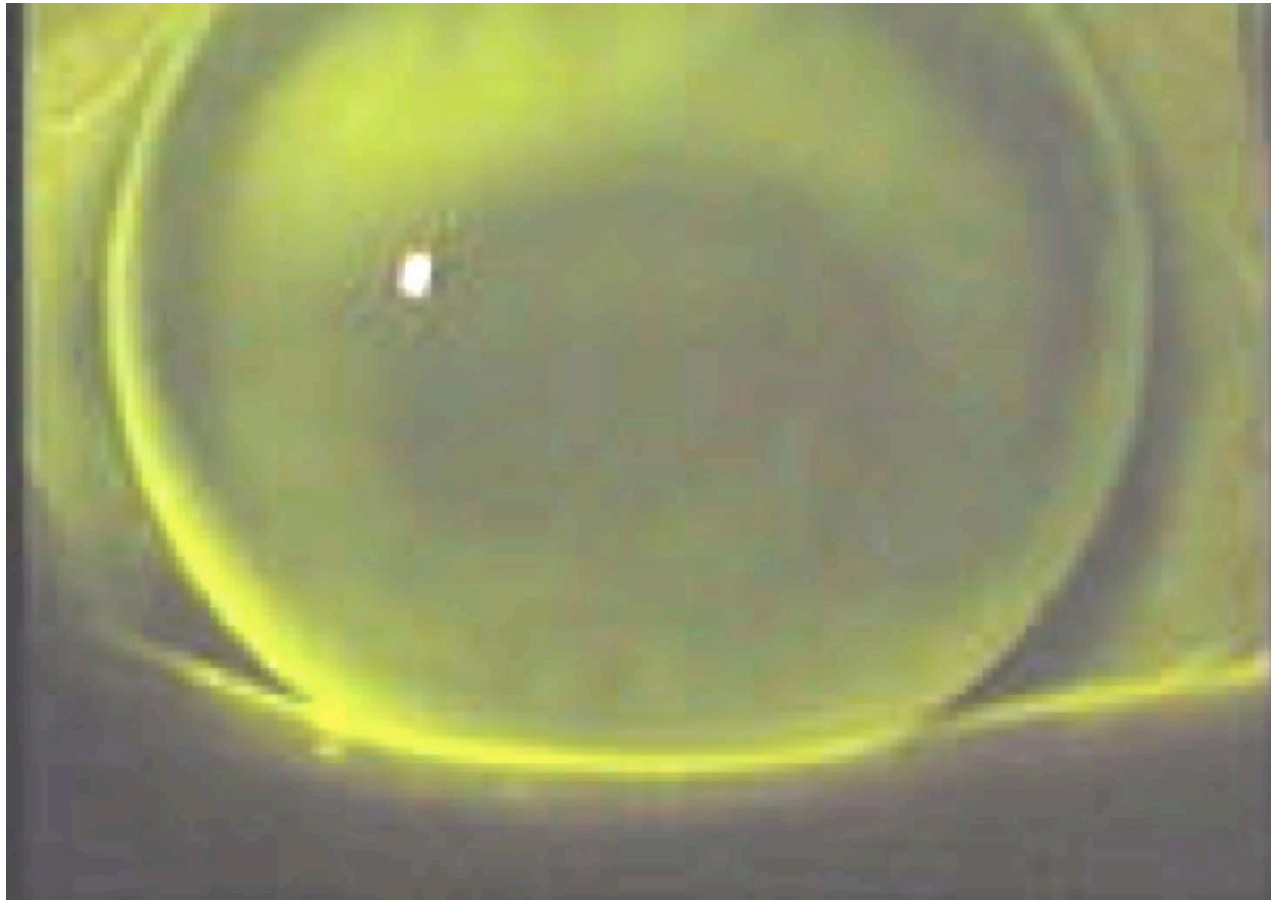
Diagnostic Fitting the I-Kone Designs



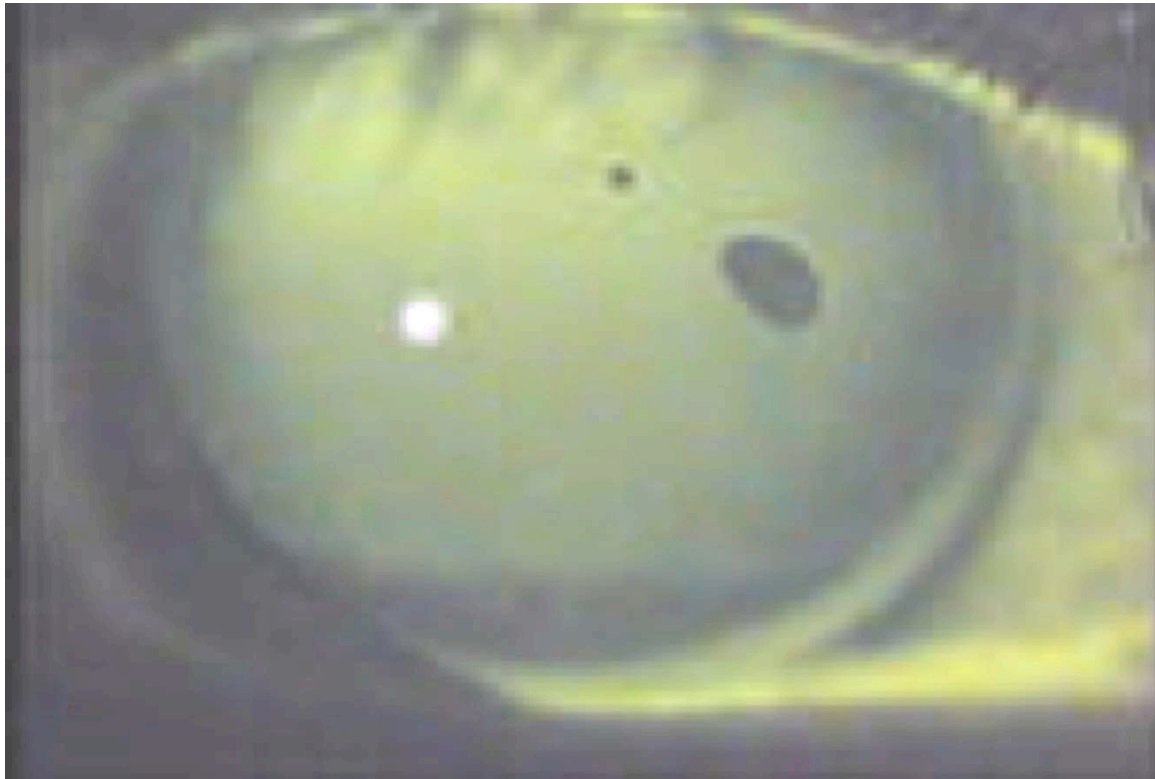
DynaZ Intralimbic alignment fit



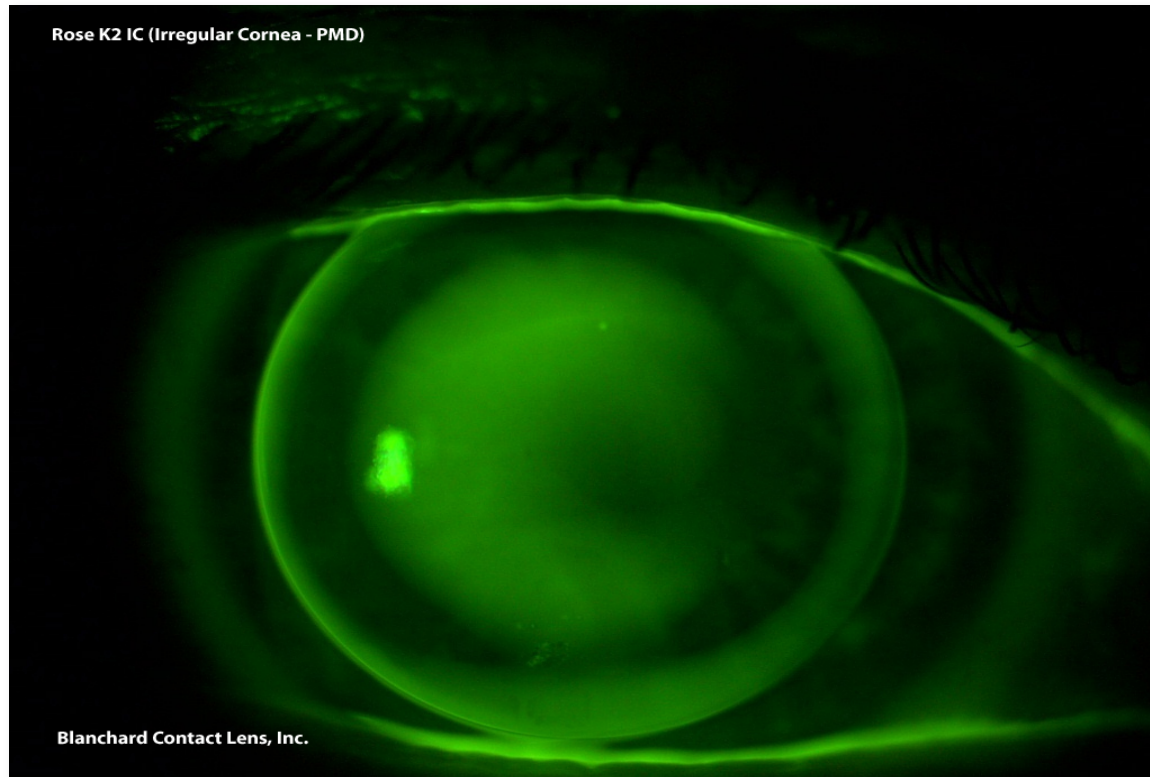
DynaZ Intralimbal flat fit



DynaZ Intralimbals steep fit



Rose K2 IC



Advantages of Intra-Limbal Lenses

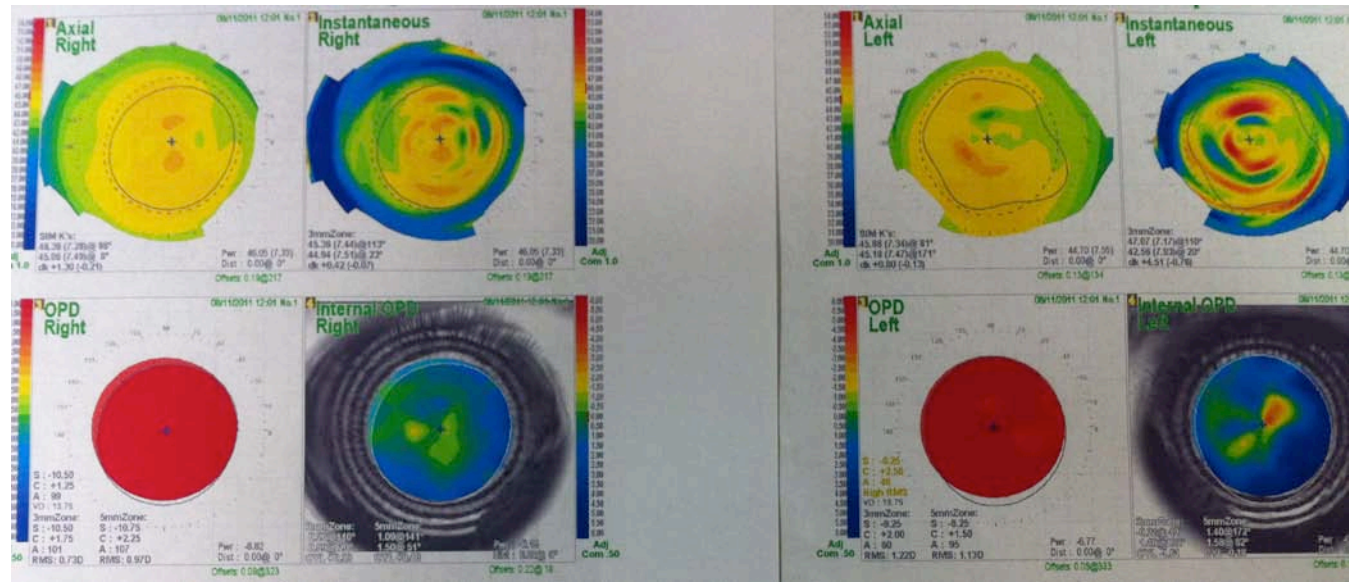
- Better centration and stability
- Good vision
- Better initial comfort

Disadvantages

- Patients may have more difficulty with insertion and removal

Kenneth

- 49 year old African American male
- Office worker
- h/o KCN with atypical topography for KCN with irregular astigmatism
- sim Ks
OD 47.25 @ 029 / 37.25 @ 119
OS 45.75 @ 174 / 48.25 @ 084



Kenneth

- Entering VA (with GP CLs)
- OD 20/40+2
- OS 20/40

- OD - 2+ temporal PEK, no Fleisher ring, no striae or thinning
- OS - 1+ temporal PEK, no Fleisher ring, no striae or thinning

Kenneth

Contact lenses

- OD F60 45.25 / -7.25 / 8.8
- OS F60 45.50 / -5.75 / 8.8

- Fit could be improved
- Interpalpebral with inferior decentration
- Excessive movement OD

- Patient interested in monovision

Kenneth

New contact lenses

- OD Oxy HDS 44.50 / -4.50 / 11.0 (N)
- OS Oxy HDS 44.50 / -6.00 / 11.0

- OD 20/40-2 with -2.00 20/25-2
- OS 20/25+2 SOR +0.25 NI

Fit

- Lid attachment, centered
- Alignment
- Good peripheral systems

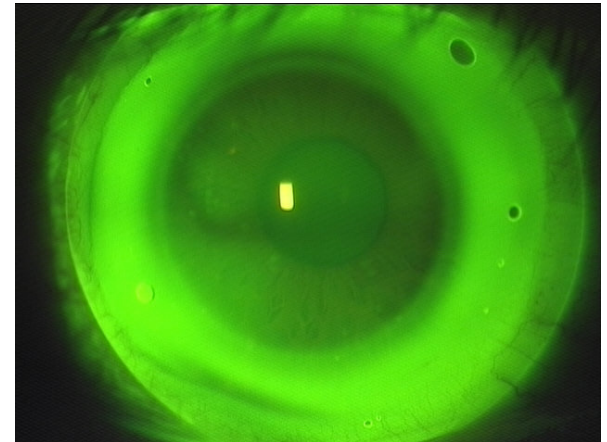
Scleral Lenses



La Ser Eye Jewelry
Dr. Chandrashekahr Chawan

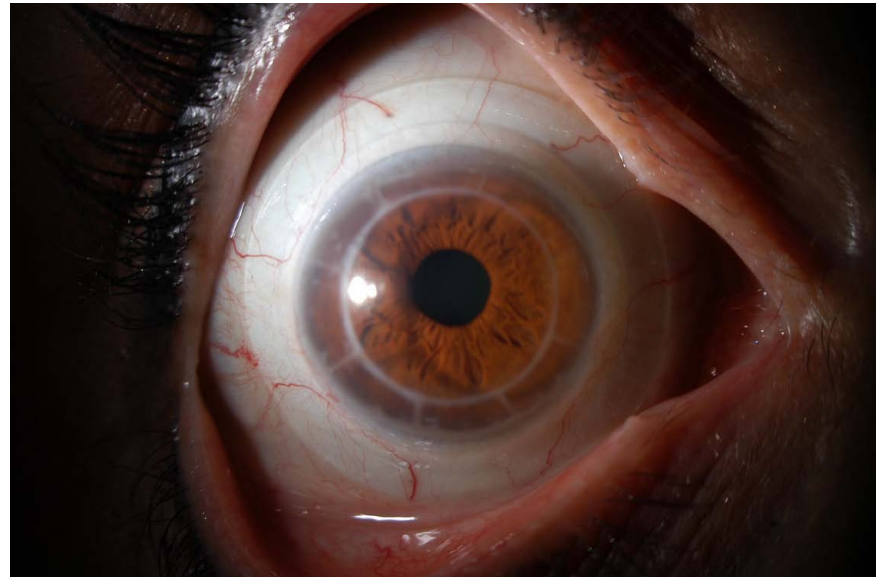
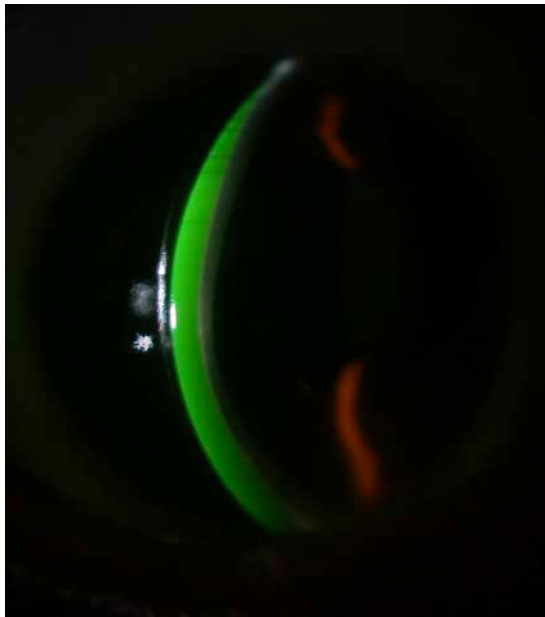Scleral Lens Classification

- Classification designed by Dr. Rob Breece
- **Corneo-Scleral**
 - Corneal bearing and scleral touch
 - 12.9 - 13.5mm
 - Limited tear reservoir capacity
- **Semi-Scleral**
 - Corneal and scleral bearing
 - 13.6 - 14.9mm
- **Mini-Scleral**
 - Scleral bearing and minimal corneal clearance
 - 15.0 - 18.0mm
 - Somewhat limited tear reservoir capacity



Scleral Lens Classification

- Full Scleral
 - Scleral bearing and maximal corneal clearance
 - 18.1 - 24.0mm
 - Almost unlimited tear reservoir capacity

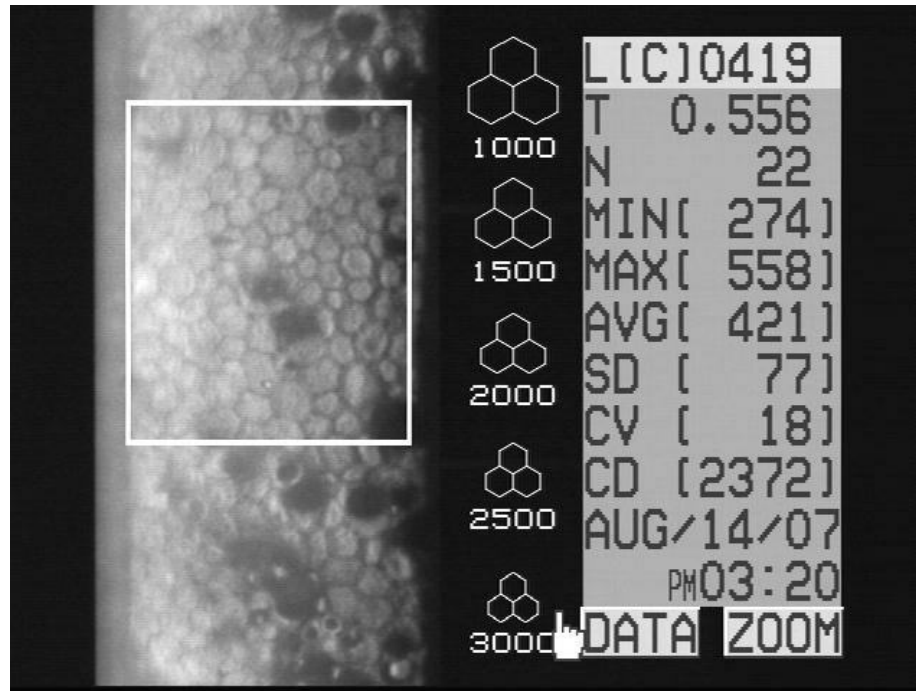


Scleral Lens Indications

- Advanced (notably decentered) cones
- Pellucid marginal degeneration
- Failure with piggyback lenses
- Poor comfort with traditional gas permeable designs
- Severe dry eyes, GVHD, stem cell deficiency, post graft...

Scleral lens Contraindications

- Corneas with significant edema from reduced endothelial cell count



Are Scleral Lenses comfortable?

They are so big!

Corneoscleral Lenses

- Corneal bearing and scleral touch
- 12.9mm to 13.5mm

Corneoscleral Lenses: Indications for Use

- Decentered irregular astigmatism
- Pellucid marginal degeneration
- Oval or globus Cones

Corneoscleral Lenses:

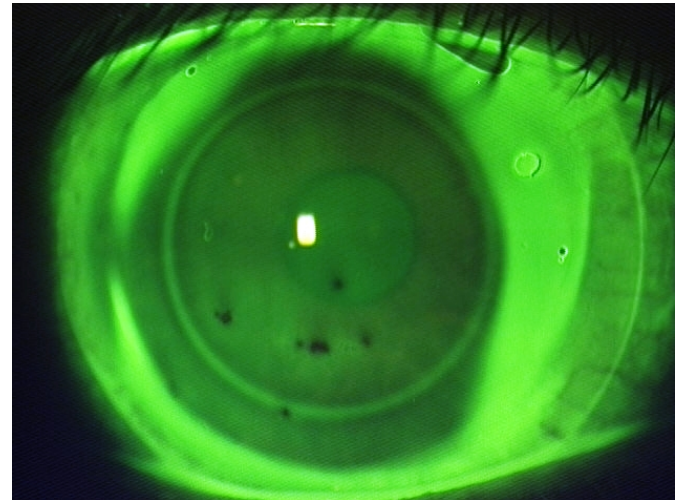
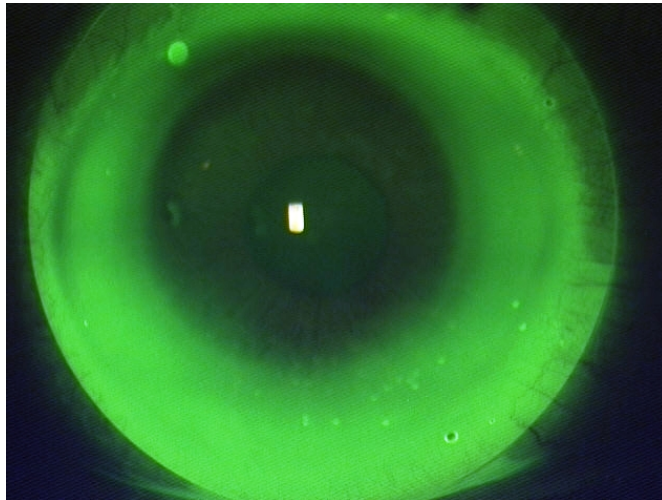
- Do not use with focal steep cone
- Do not fit if corneal epithelium cannot tolerate bearing (lens puts some pressure on the cornea)

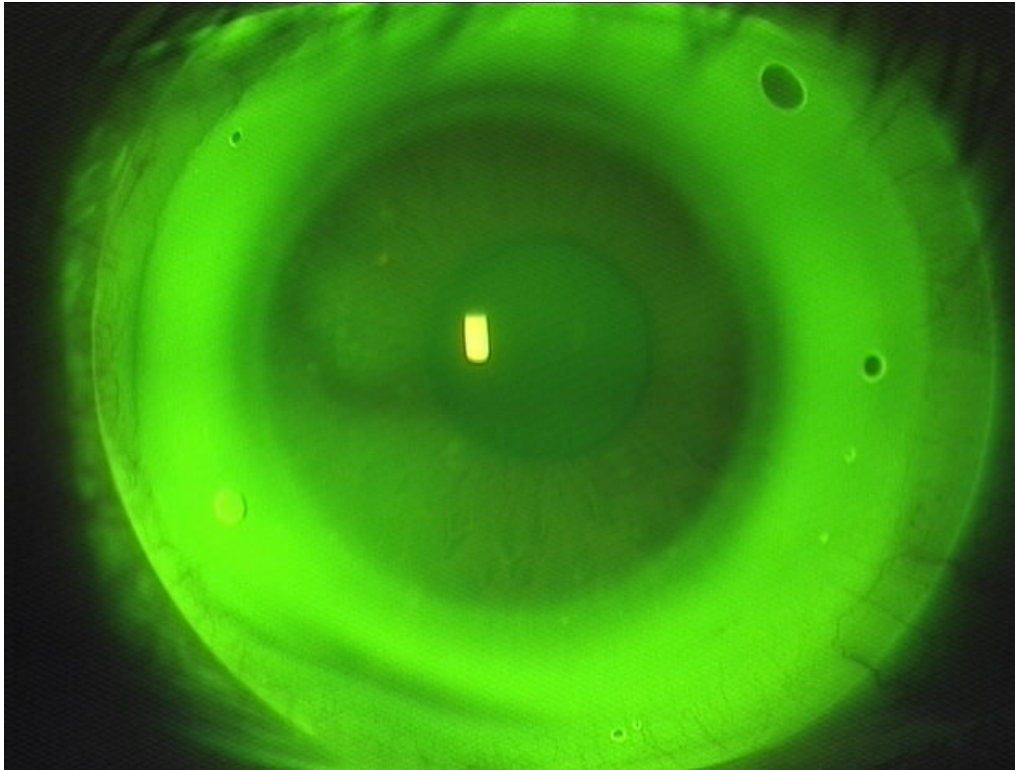
Corneoscleral Lenses (12.9mm to 13.5mm)

- Semi-Scleral
 - Abba
 - 13.5mm
- SoClear Lens
 - Dakota Sciences / Art Optical
 - 13.5 - 15.0mm

SoClear Contact Lens fitting

- Equally distribute pressure along corneal and scleral surfaces
- Central and peripheral portions of lens may be independently adjusted
- Too flat
- Too steep

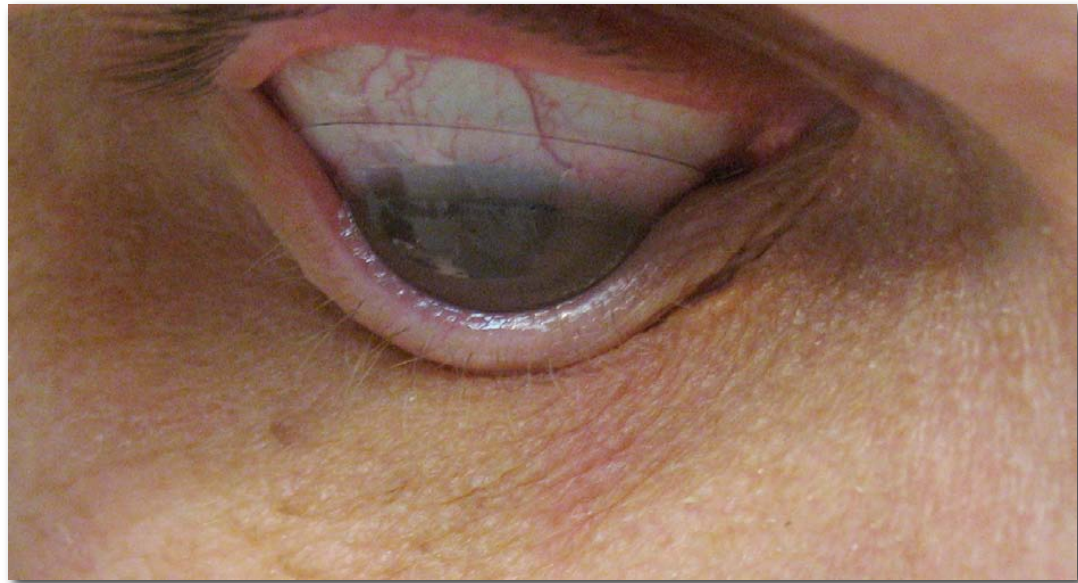



- SoClear Contact Lens
- Ideal fit
 - light feather touch at the central cornea
 - moderate mid-peripheral clearance
 - even amount of scleral bearing

Corneoscleral Lens Fitting

- Different lenses fit differently
- Lens movement desirable for all lenses



Semi-Scleral (13.6 mm to 14.9 mm)

- Corneal and scleral bearing
- Jupiter lens
 - Visionary Optics (formerly Medlens) / Essilor / ABB-Concise
 - 13.5 -16.6mm
- So2Clear
 - Art Optical
 - 14.0 mm

Mini-Scleral (15.0 mm to 18.0 mm)

- Scleral bearing and minimal corneal clearance

Mini-Scleral (15.0 mm to 18.0 mm)

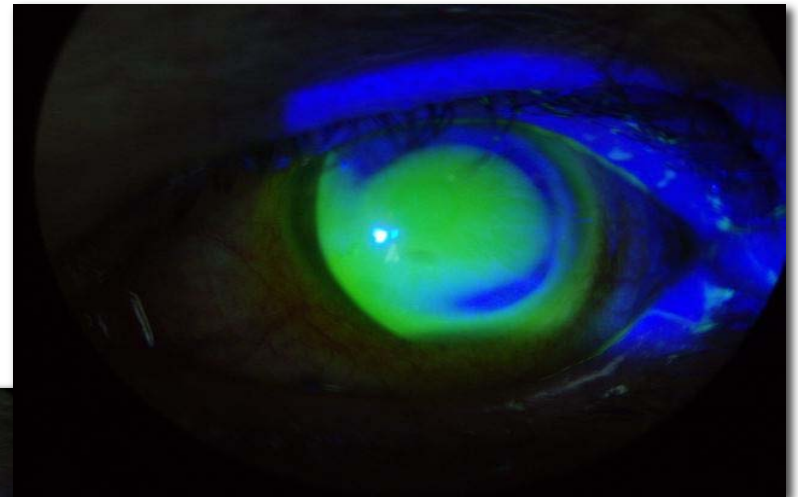
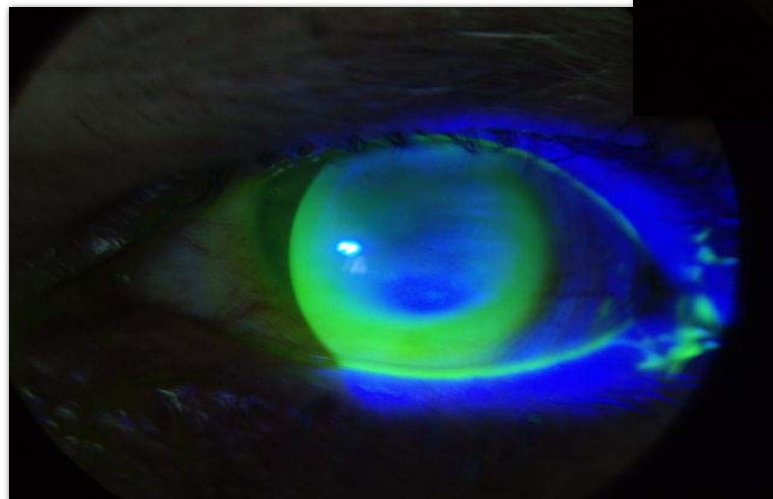
- Msd
 - Blanchard
 - 15.8mm
- Maxim
 - Acculens
 - 16.0mm
- Jupiter
 - Visionary Optics / Essilor / ABB-Concise
 - 15.0-18.8mm
- Boston MiniScleral
 - Foundation for Sight
 - 15.0-15.5mm

Jupiter Lens Fitting

- Completely vault cornea and limbus and rest on sclera
- Three zones
 - Corneal zone - includes central corneal curve and aspheric peripheral corneal curve
 - Limbal zone
 - Scleral zone - aspheric scleral curve and aspheric edge curve

Jupiter Lens Fitting

- Fit on principle of sagittal depth
 - Sagittal depth too high, leads to central bubbles
 - Sagittal depth too low, excessive central touch and bubbles in the sclera



8.2mm Optical Zone
54.00 BC or 6.25 Radius

PC 1 with 2.0mm travel
6.65 Radius

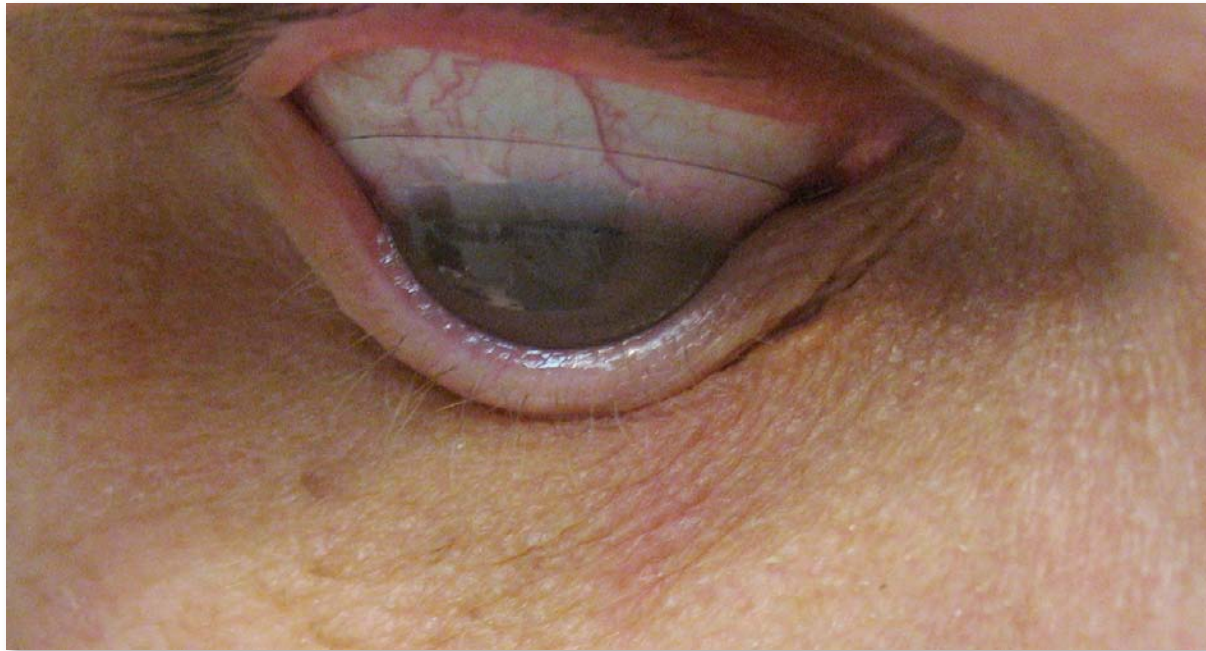PC 2 with 1.0mm travel
Limbal Bridge
8.80 Radius

PC 4 with 1.5mm travel
Scleral Haptic
12.25 Radius

PC 5 with 0.5mm travel
Edge Lift for tear exchange
14.50 Radius

Chord Diameter = 18.2mm

Material: Tyro 97 with UV Protection
Hofocn A dK=97 Specific Gravity=1.122 Wetting Angle=23



- Jupiter 18.8mm 60 diopter lens with a 2 mm flatter scleral curves
- Reverse geometry design

Pictures courtesy of Dennis Neifert, Essilor, USA

Don, 55 year old Caucasian male

- Date of examination - 11/16/10
- History of KCN
- History of discomfort with gas permeable contact lenses, especially on windy days
- Glaucoma suspect, monitored by glaucoma service

Don

VA with GP CLs

OD 20/30-2

OS 20/30-2

Manifest Refraction

OD -6.00+1.75x180

20/25

OS -6.00+2.00x180

20/30-2

Don

Corneal topography Sim Ks

OD 46.94 @ 158 44.82 @ 068

OS 46.42 @ 026 43.60 @ 116

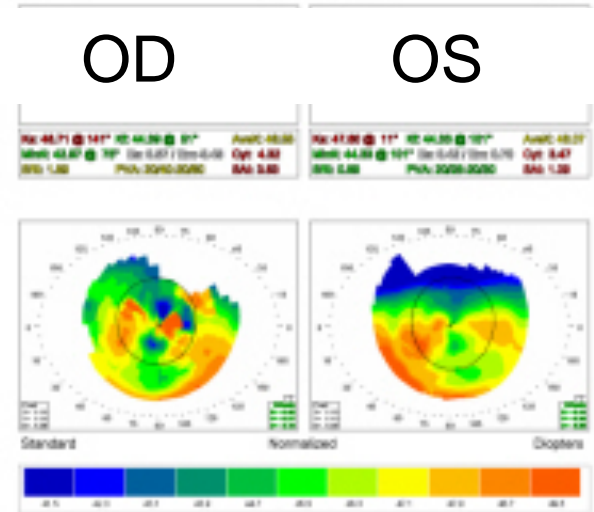
Inferior steepening with
kissing bird sign OU

Cornea

- Inferior Fleisher ring in both eyes

Lens – clear OU

Dilated examination - C/D 0.60 OU macula normal OU



Don

- Impression
- Keratoconus OU.
- Fit could be improved with GP contact lenses, however patient interested in scleral lenses for improved comfort.

Don Scleral Lens Fitting

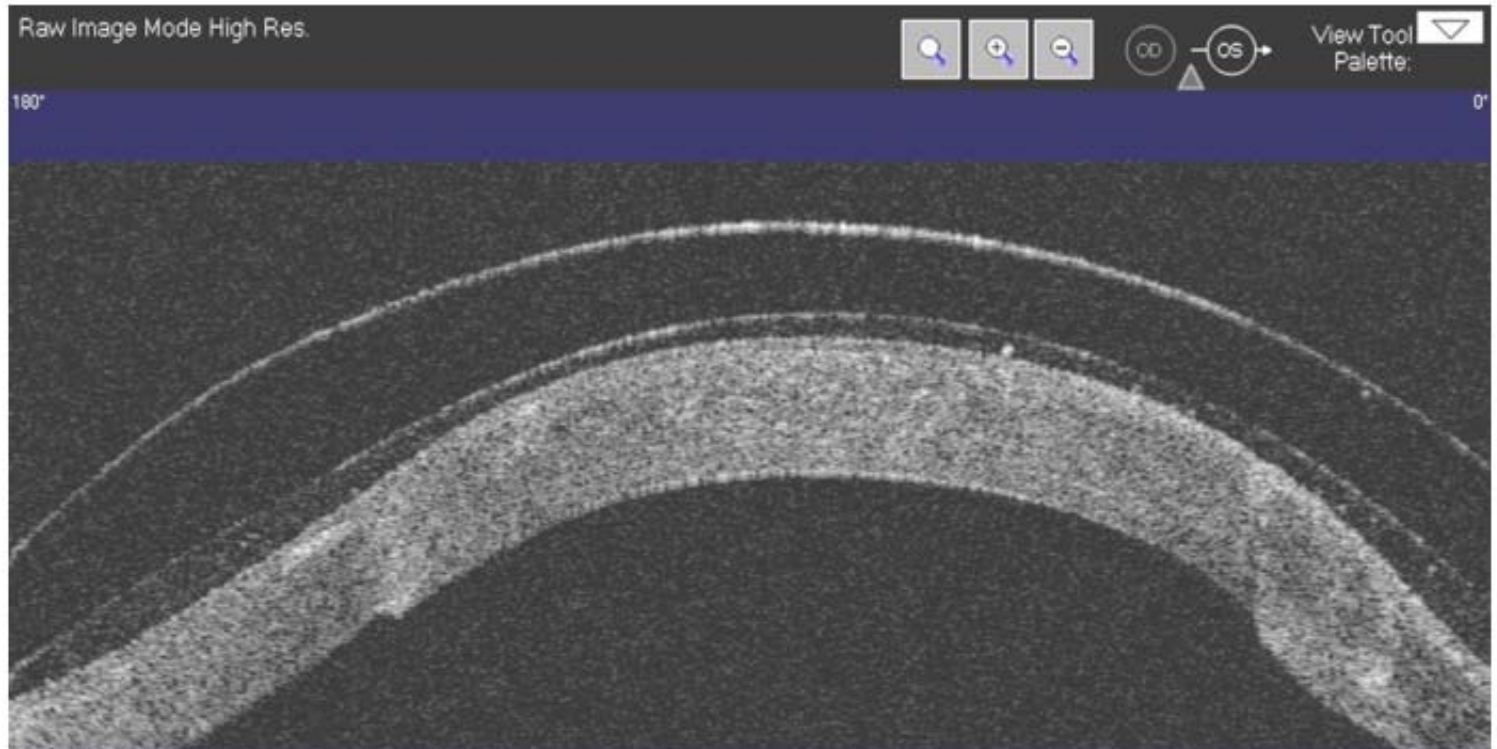
- Initial best fitting Jupiter scleral lenses
- OD Jupiter 49.00 / - 9.00 / 15.6
With +1.00DS 20/25-2
- OS Jupiter 49.00 / - 9.00 / 15.6
With +0.75 20/25

Don Scleral Lens Fitting

- Ordered lenses with larger diameter and chamber size due to fit (not enough clearance superior nasal)
- OD Jupiter 48.00 / - 7.00 / 16.0 / 13.25 / 14.75 Ice blue
- OS Jupiter 48.00 / - 7.25 / 16.0 / 13.25 / 14.75 Ice blue
- Advised need for reading glasses over contact lenses.

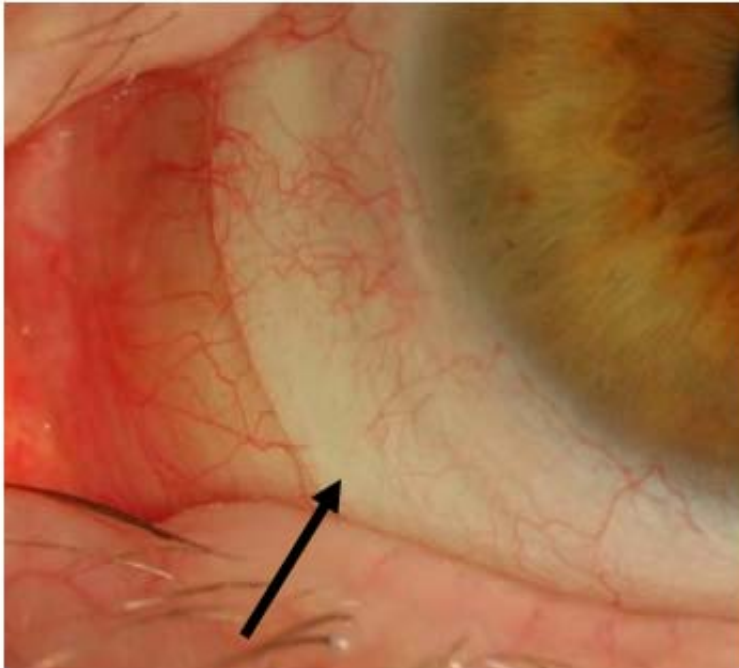
1.

Bridge Over The Cornea and Limbus

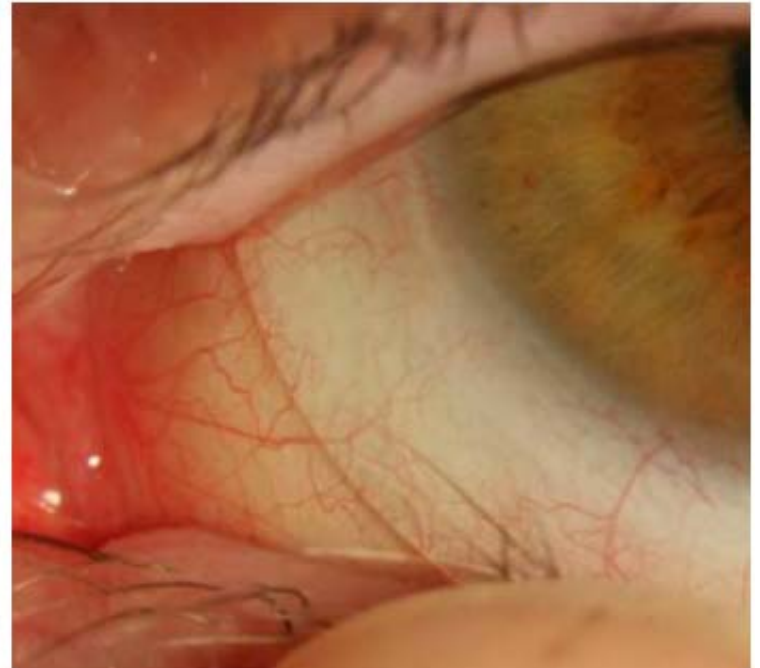


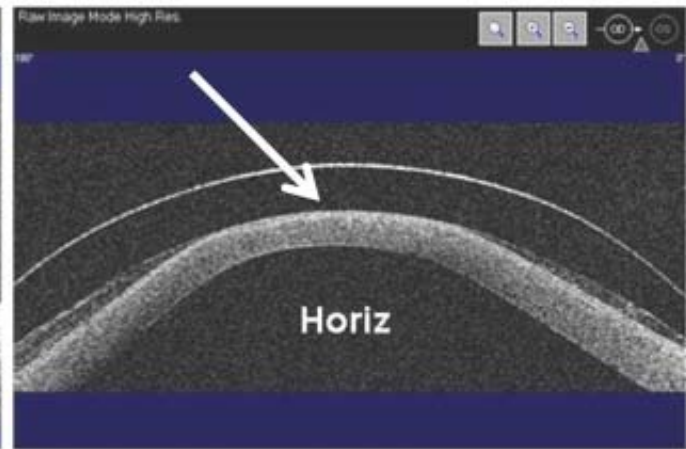
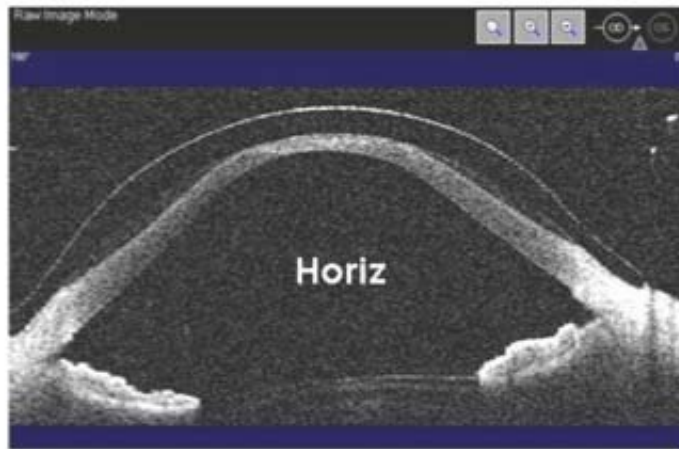
2. “Landing” Not Too Flat Or Steep

Avoid a lot of blanching

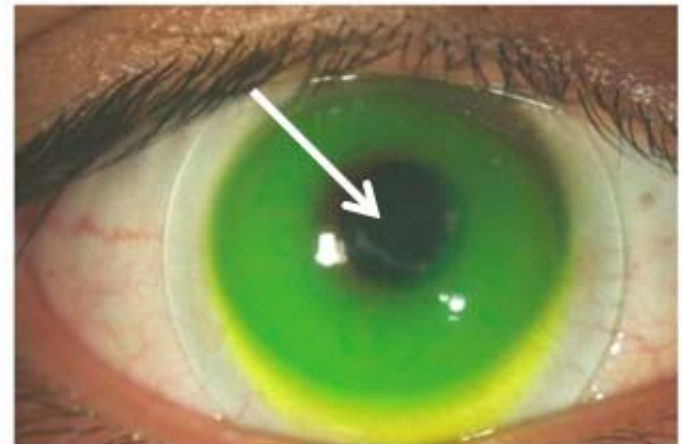



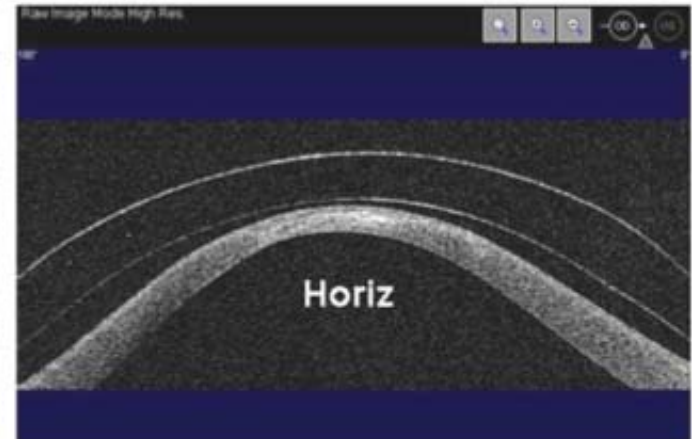
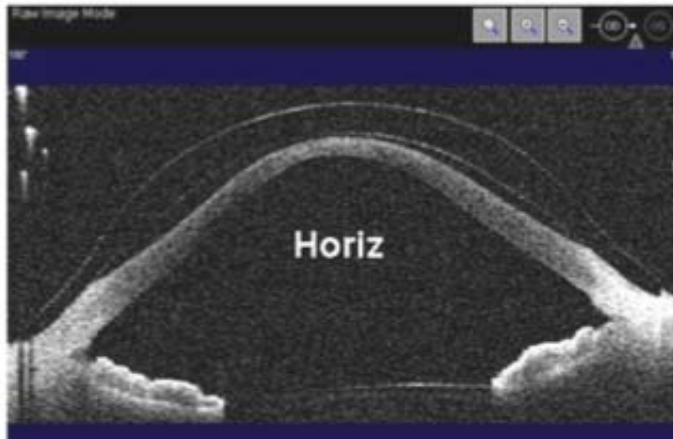
Vessel fills with finger pressure



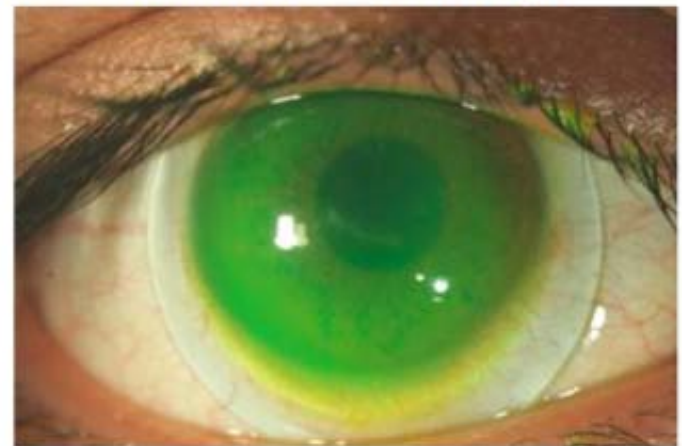
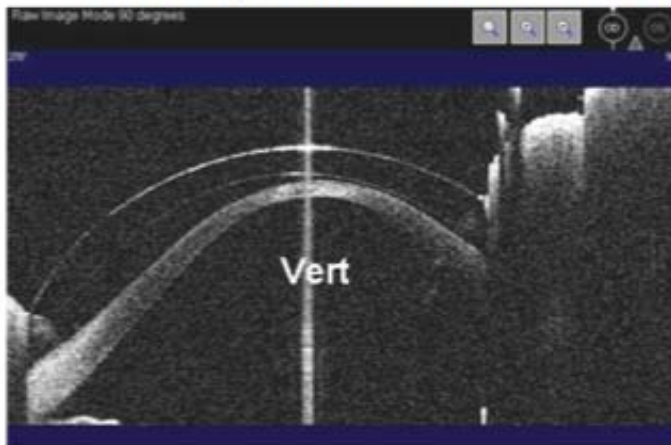


**Example: Pt ED, Keratoconus, Jupiter 15.6mm, 5100D
Lens fits flat centrally. Corneal touch at arrows.**





Steepen central base curve by 3D to 5400D and lens fits with apical clearance. Note no blanching at landing.



John, 51 year old Caucasian Male

- Date of examination - 4/13/09
- History of KCN x 20 years since 30 years old
- Sister also has KCN
- Tried soft, hard and hybrid contact lenses (most recently 10 years ago) without success.
- Rigid lens improved vision OD, however unable to tolerate lens.
- Right eye vision is deteriorating. Left eye vision is very poor.
- Lights have rings around them like halos.

John

- Medical history – seasonal allergies
- Family history – no significant history
- Social history – state office worker, lots of computer work.
- Hobby - reading
- Ocular Medications – none
- Systemic Medications – Claritin, steroid nasal spray, MVI

John

VA corrected with glasses

OD 20/30+2

OS 20/150 -1

PH 20/60+2

Manifest Refraction

OD -4.75+3.00x170 20/25

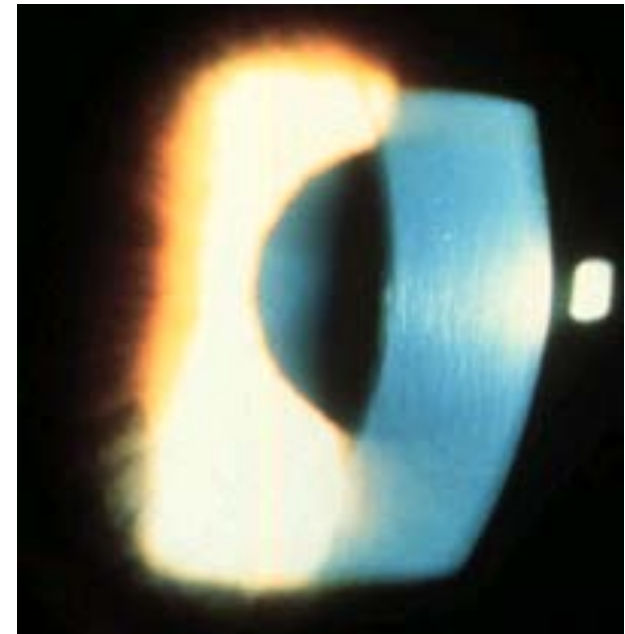
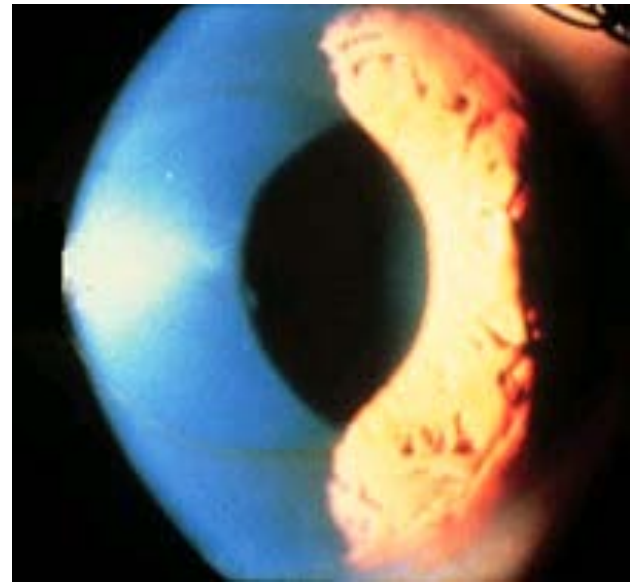
OS -9.25+4.50x120 20/60

John

Cornea

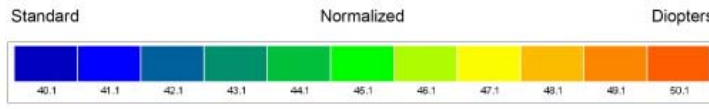
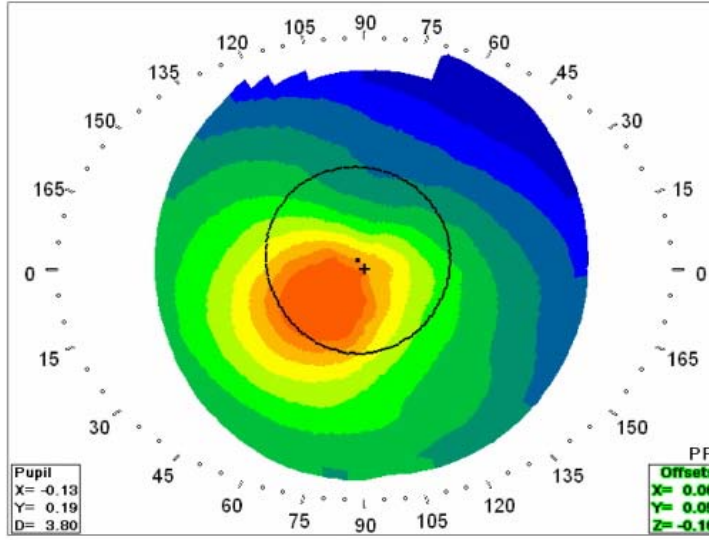
OD - inferior Fleischer ring,
paracentral inferior thinning

OS - Vogt's striae centrally,
inferior Fleischer ring,
paracentral inferior thinning



OD

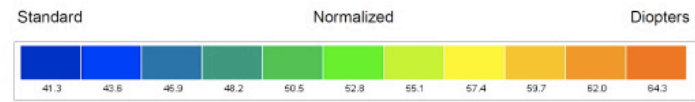
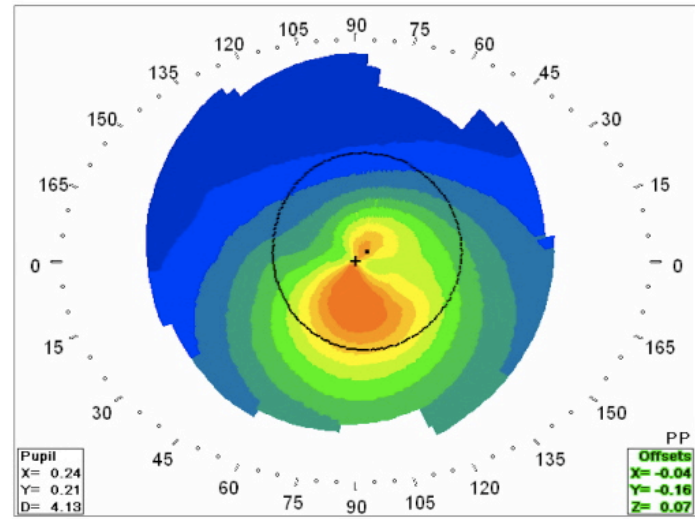
Ks: 48.43 @ 35° Kt: 48.23 @ 125° MinK: 45.08 @ 111° AvgK: 47.33 Cyt: 2.19
SFR: 0.48 Iax: 0.878 / Irm: 0.81 PVA: 20/20-20/25 SAI: 1.71



OS

Date: 4/14/2009 4:14:14 AM Exam 2

Ks: 60.39 @ 69° Kt: 52.82 @ 159° MinK: 52.88 @ 167° AvgK: 58.80 Cyt: 7.57
SFR: 1.85 Iax: 0.877 / Irm: 0.846 PVA: 20/40-20/60 SAI: 3.27



Corneal topography Sim Ks
OD 48.43 @ 036 / 40.23 @ 125
OS 60.39 @ 069 / 52.82 @ 159

John

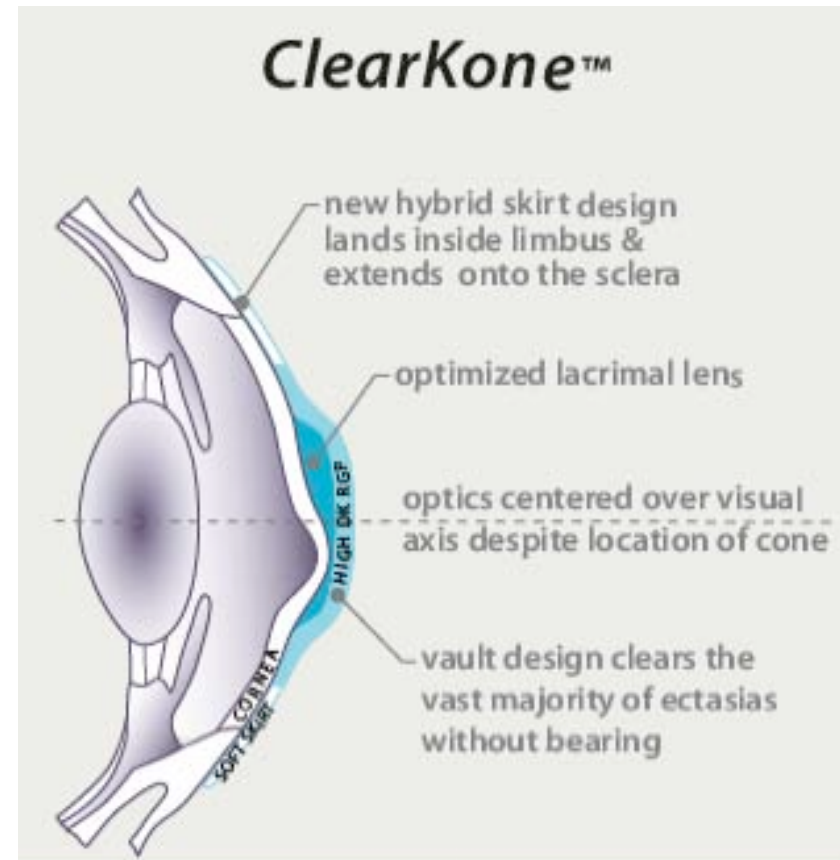
Pachymetry OD 491 μ m OS 446 μ m

Dilated examination – normal OU

Diagnosis - Keratoconus OU

John - Contact Lens Fitting

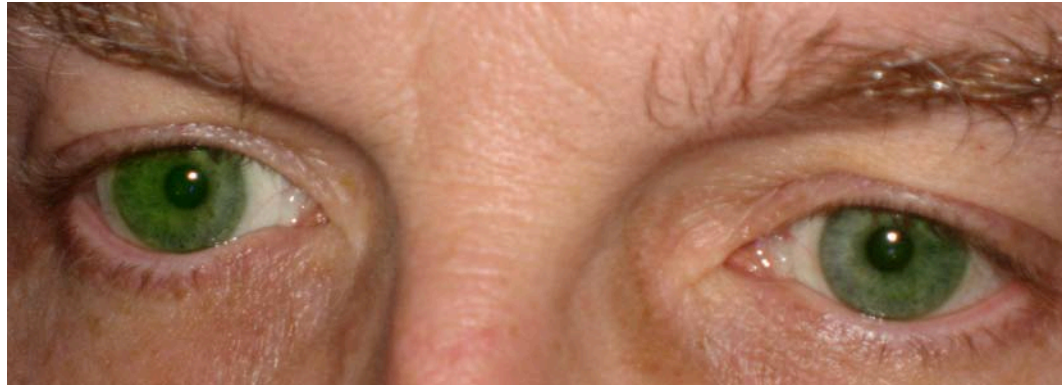- Clear Kone
- OD Vault 200 / -2.00 / medium skirt
20/20-2
- OS Vault 350 / -5.50 /
medium skirt
20/25+2



John - Contact Lens Fitting

- Follow up, limited CL wear due to irritation OS
- New lens fit OS
- Clear Kone Vault 300 / -2.75 / steep
- 20/25

- Follow up #2
- Left eye poor comfort, only able to wear lenses 2 hours
- Refit to Jupiter scleral lenses



John Scleral Contact Lens Fitting

Best fitting lenses

OD Jupiter 49.00 / -9.00 / 18.2

With +1.00DS 20/25+2

OS Jupiter 50.00 / -9.00 / 18.2

With +0.25DS 20/30+2

Fit

OU good central apical clearance, good peripheral fit, well centered, good movement, no blanching

John Scleral Lens Dispense

OD Jupiter 49.00 / -8.00 / 18.2

VA 20/25+1 SOR -0.50 NI

OS Jupiter 50.00 / -8.75 / 18.2

VA 20/25-2 SOR +0.25 NI

Binocular VA without SOR 20/20-2

Fit

OU good central apical clearance, well centered, good movement,
no blanching

John - Scleral Lens Follow Up

Vision? Sees a shadow in each eye which is hard to ignore. It is bothersome to not be able to read without reading glasses.

Comfort? Good

OD Jupiter 49.00 / -8.00 / 18.2

VA 20/30-2 SOR -0.50 20/25+1

OS Jupiter 50.00 / -8.75 / 18.2

VA 20/30+2 SOR pl

Binocular VA without SOR 20/20-2

John

Impression

Good overall fit OD, more clearance needed OS

Patient interested in monovision

Plan

Ordered

OD Jupiter 49.00 / -8.50 / 18.2

OS Jupiter 50.50 / -7.25 / 18.2 (near)

Advised non-preserved artificial tears PRN

John New Scleral Lenses

Vision? Much improved except sees shadows when reading very small letters up close.

Happy with monovision.

Comfort? Very good.

OD Jupiter 49.00 / -8.50 / 18.2

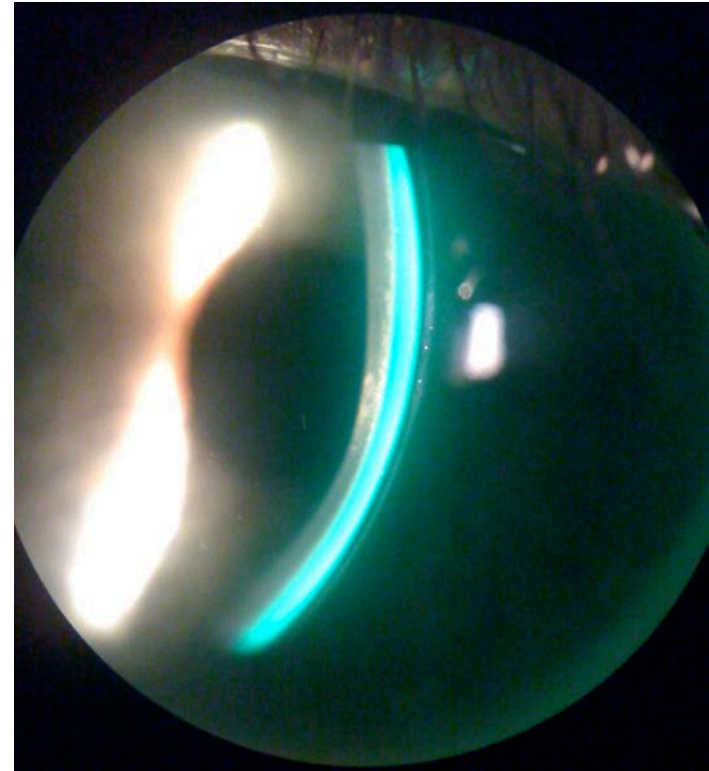
VA 20/25+2 SOR -0.25 20/20-2

OS Jupiter 50.50 / 7.25 / 18.2 (near)

VA 20/70 J1+ with -1.50DS 20/25+2

- Impression
- Good overall fit, vision and comfort with Jupiter scleral lenses
- Good adaptation to monovision

- Plan
- Continue contact lens wear for daily wear.
- Reviewed solutions - Lobob cleaner, Boston conditioner and Unisol for insertion.
- Non-preserved artificial tears as needed.
- Follow up in 4 months for a scleral lens check / PRN.



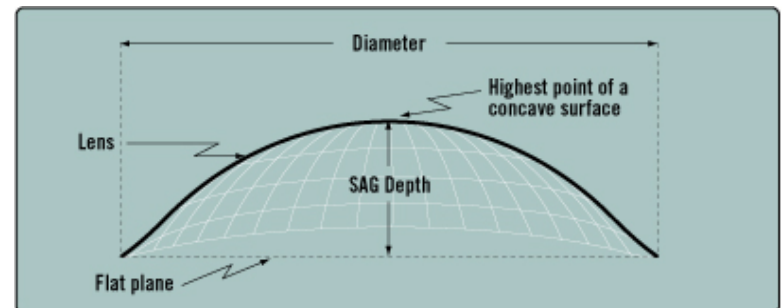
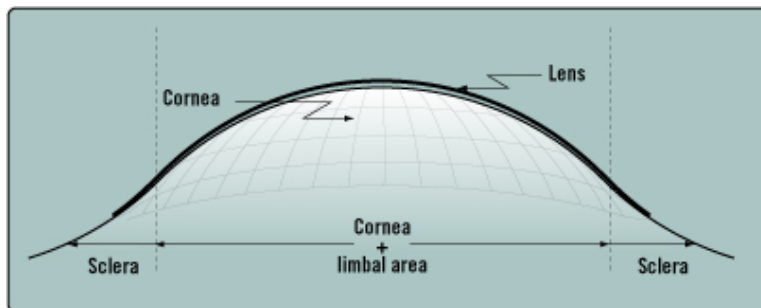
Msd Fitting



- 15.8 mm
- Central optic zone - apical clearance or feather touch
- Mid-peripheral limbal zone - vaults the limbus and aligns with the sclera
- Posterior surface incorporates reverse geometry
- Sagittal depth is adjusted independently of central optic zone profile

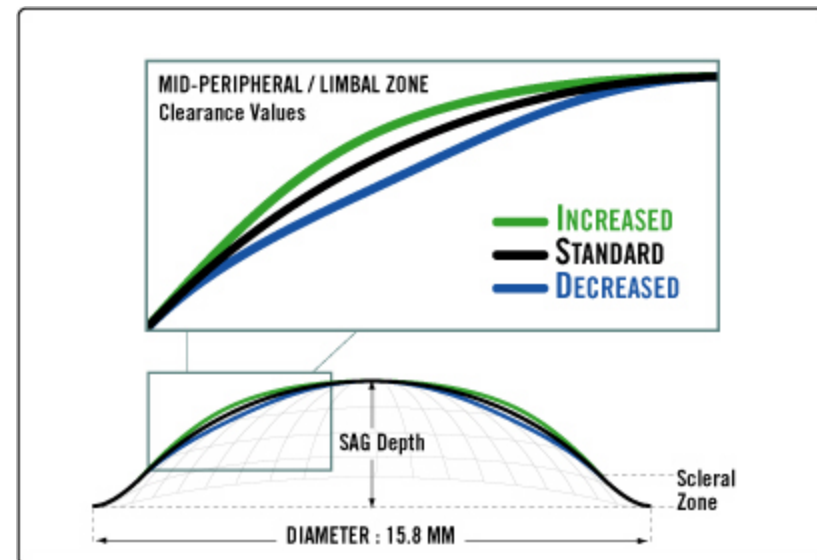
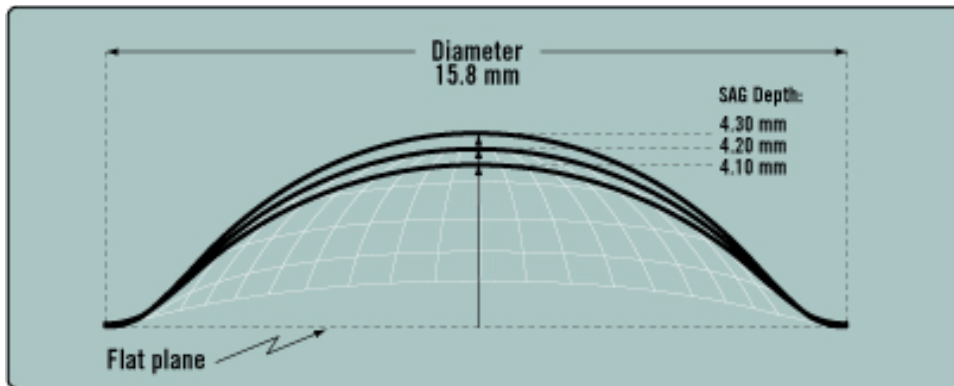
Sagittal Depth

- Sagittal depth is the measurement from the flat plane to the highest point of a concave surface
- If sagittal depth is too high, leads to central bubbles
- If sagittal depth is too low, leads to excessive central touch and bubbles in sclera

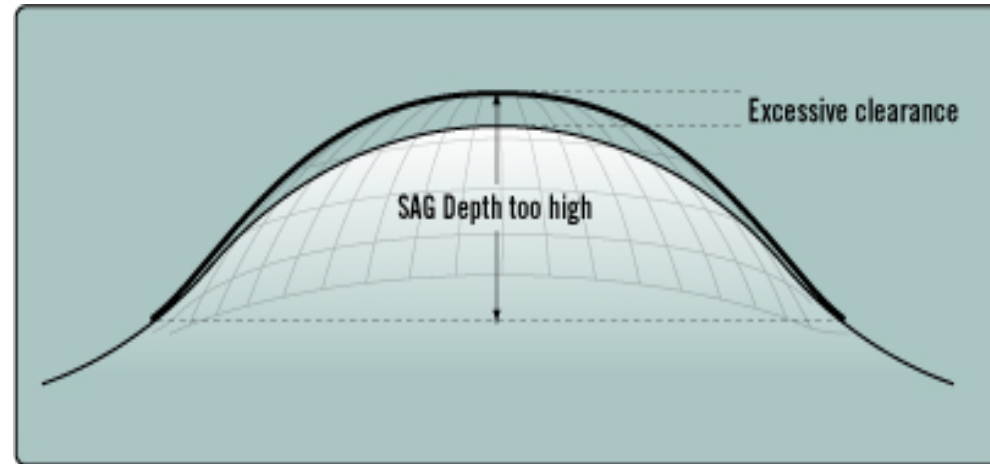
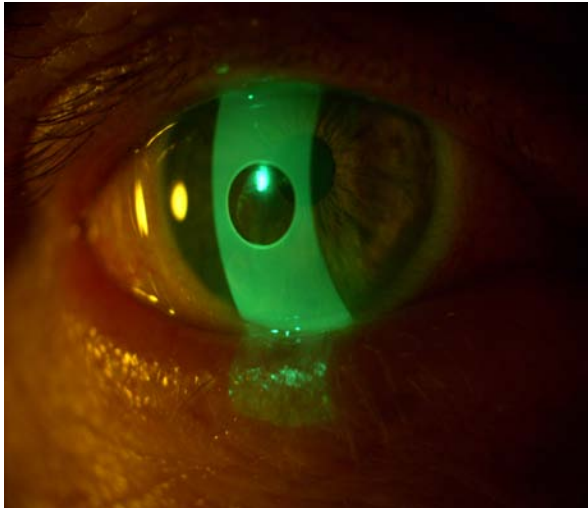

Msd Fitting

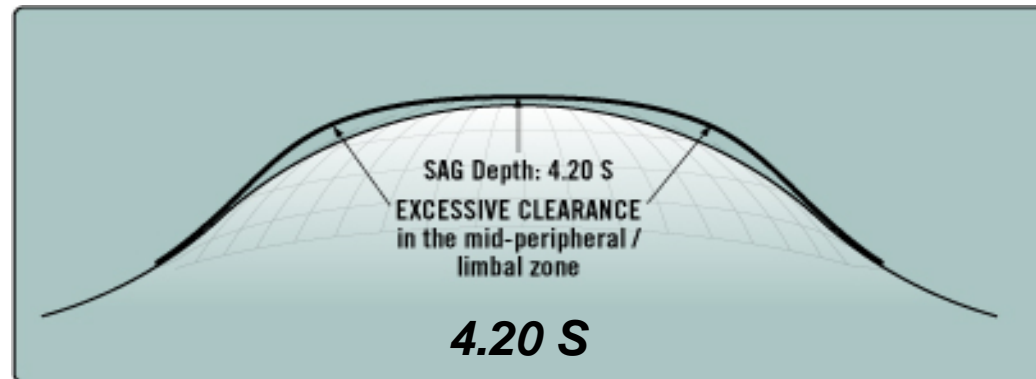
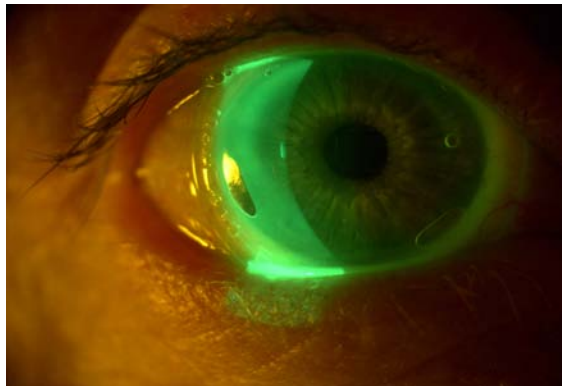
- With each sagittal depth value, there is the option of three Mid-Peripheral / Limbal Clearance Values
- Standard, increased and decreased

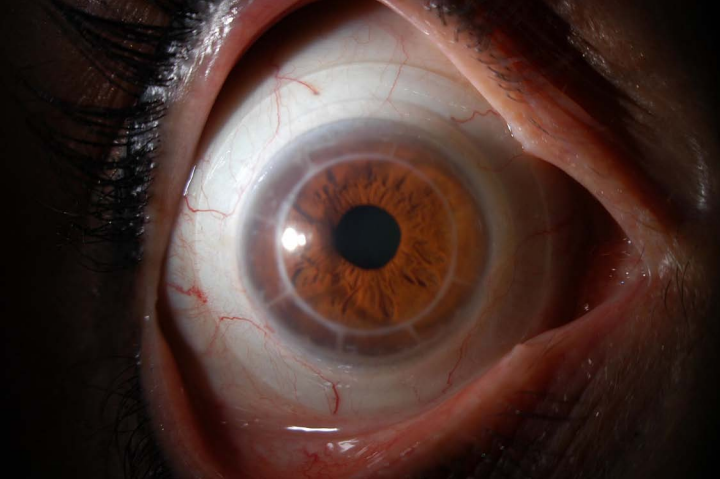


Excessive sagittal depth - bubbles centrally



Excessive Mid-peripheral clearance - bubbles in mid-peripheral / limbal zone





Full Scleral Lenses (18.1 mm to 24.0mm)

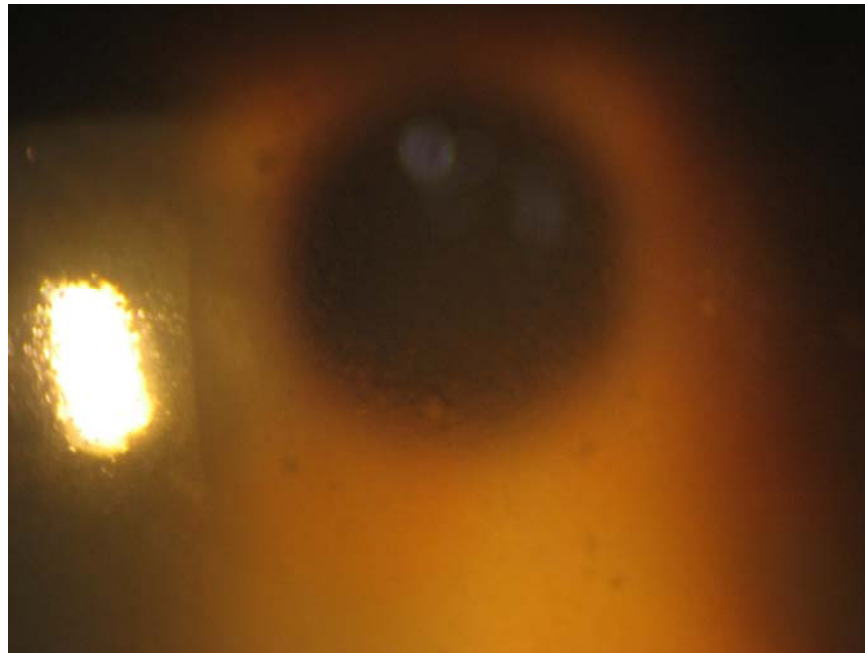
- Scleral bearing and maximum corneal clearance
- First used in late 1800s and early 1900s
- Manufacturing process now more reproducible
- Modern scleral lenses
 - Don Ezekiel, O.D.
 - Perry Rosenthal, M.D. Boston Scleral Lens

Advantages

- Good centration
- Good stability
- Stable vision and optics
- Good initial comfort

Disadvantages

- Insertion / removal difficult with larger diameters
- Worse tear exchange





Handling - Lens Insertion

- Goal “bubble free” insertion
- Patient bends over so that patient’s face is parallel to the horizontal plane
- May use target for patient to look at (such as Amsler grid) when training
- Fill scleral lens fully with fluid

Handling - Scleral Lens Insertion

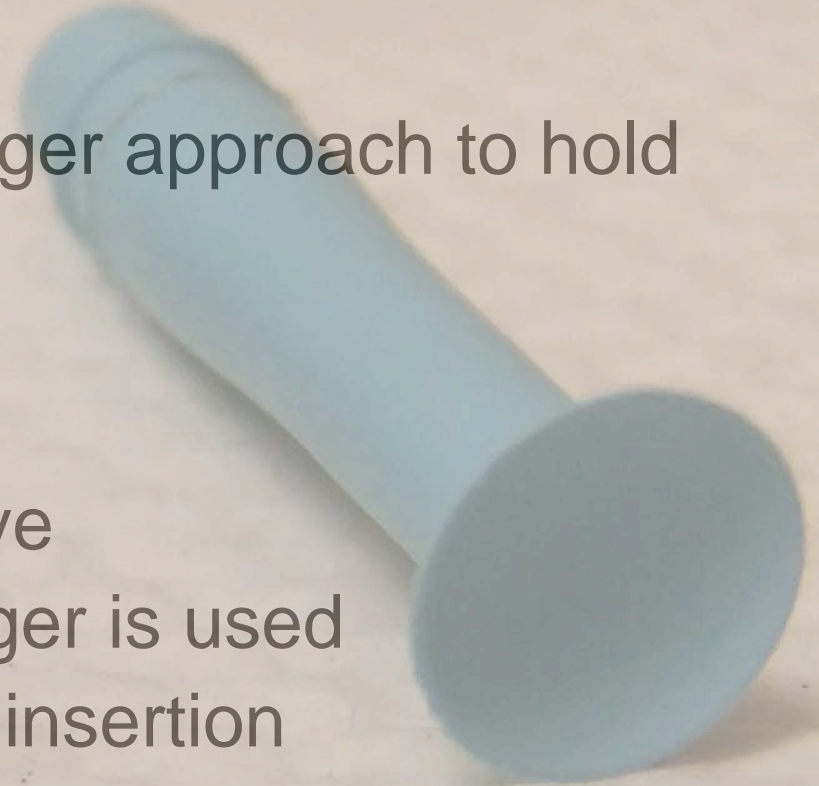


Handling - Lens Insertion

- Use plunger or three finger approach to hold the lens
- Three finger method
- Three fingers are thumb, index, and middle fingers (may use ring finger also)
- Hold eyelids open
- Place the lens on the eye

Handling - Lens Insertion

- Use plunger or three finger approach to hold the lens
- Plunger method
- Hold eyelids open
- Place the lens on the eye
- Release plunger if plunger is used
- Prefer large plunger for insertion



Handling - Lens Removal

- Manual two finger method
- Have patient look down
- Move lower eyelid outward while applying mild pressure to eyeball
- Then gently push lower eyelid with index finger underneath the lower edge of the lens
- Remove the lens

Handling - Lens Removal

- Plunger method
- Squeeze plunger to induce suction
- Apply plunger to periphery of lens
(not to center of lens)
- Twist and pull away from eye
- Remove the lens

Soft Lenses and Soft Toric Lenses: Indications

- Early keratoconus
- Decentered keratoconus
- Globus-like keratoconus
- Poor comfort / wearing time / lens tolerance with RGP lenses

Soft Lenses and Soft Toric Lenses

- Fit centered over cornea

Advantages

- Good comfort
- Lower cost when not a custom lens

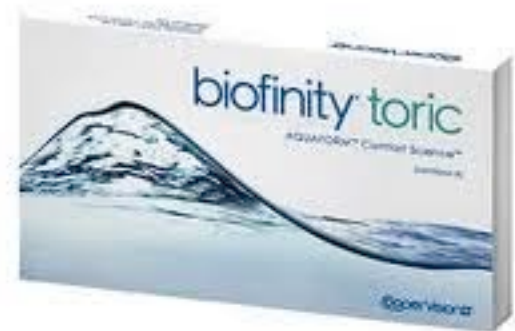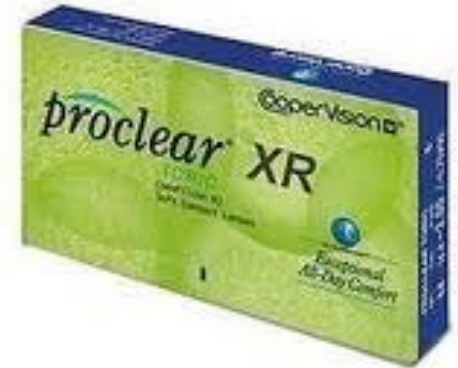Disadvantages

- Low oxygen permeability: hypoxia and corneal neovascularization
 - Better oxygen permeability with silicone hydrogel lenses
- Absence of tear lens
 - soft lens front surface reflects irregular corneal surface

Non-Custom Toric Contact Lenses

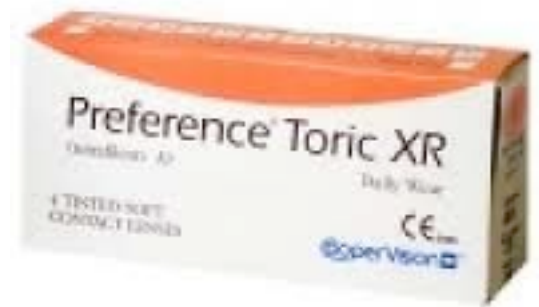- Proclear Toric (XR) (Cooper Vision)
 - Omafilcon A / 59% water
 - BC 8.4 , 8.8
 - Sphere pl to +/- 10.00
 - Cylinder -0.75 to -5.75 in 0.50 D steps (axis full circle in 5 degree steps)

- Biofinity Toric
 - Biofinity Toric (Cooper Vision)
 - Comfilcon A / 48% water
 - BC 8.7
 - Sphere +8.00 to -10.00D
 - Cylinder -0.75 to -2.25 in 0.50D steps (axis full circle in 10 degree steps)



Non-Custom Toric Soft Contact Lenses Continued

- Metrosoft Toric (Metro Optics)
 - BC 8.4, 8.7, 9.0
 - Sphere +/- 5.25 to +/- 10.00
 - Cylinder -0.75 to -8.00 (axis full circle 5 degree steps)
- Preference Toric (XR) (Cooper Vision)
 - Tetrafilcon A / 43% water content
 - BC 8.4 , 8.7
 - Sphere +6.00 to -9.50
 - Cylinder -0.75 to -9.75
(axis full circle in 5 degree steps)



Custom Soft Contact Lenses

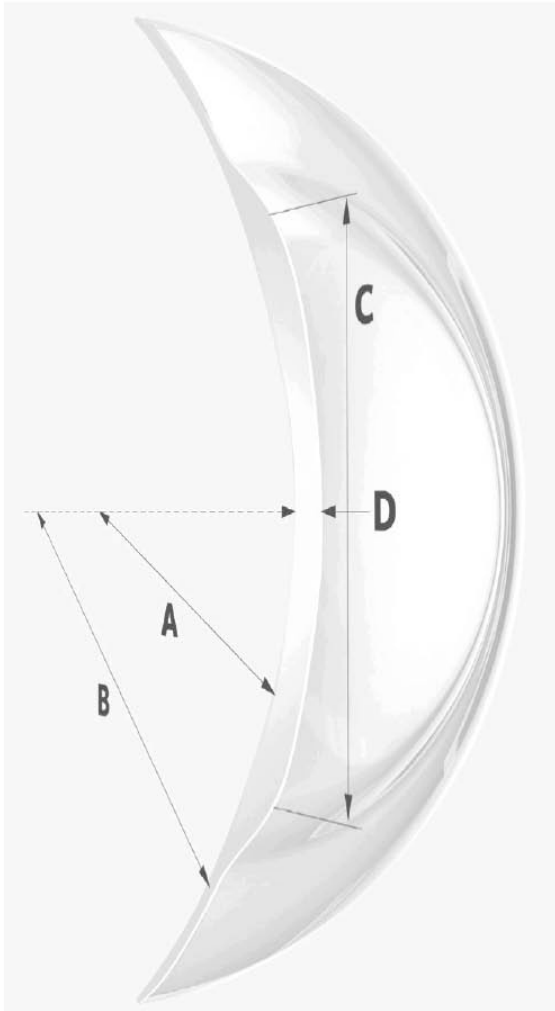
- SpecialEyes 59 / 54 Toric (SpecialEyes, LLC)
- HydroKone (Visionary Optics)
- Soft K (Advanced Vision Technologies)
- Solus Soft K (Strategic Lens Innovations)
- Ocu-Flex Toric (Ocu-Ease)
- KeraSoft IC (Bausch + Lomb)
- NovaKone (Alden Optical)

- Base Curves 6.0 -7.0mm
- Hydrocone 4.1mm BC
- Relatively flatter paracentral curve ~ 8mm to match high eccentricity of the eye

NovaKone

- Soft lens for keratoconus
- May be used for pellucid marginal degeneration

NovaKone Design



LENS CROSS-SECTION

- A. Base Curve to match average central Ks
- B. Independent Fitting Curve to optimize lens position and movement
- C. Aspheric Optical Zone
- D. Multiple “IT” factors to neutralize irregularity

NovaKone Design

- Dual Elliptical Stabilization
 - Toric stabilization for orientation and stability
 - More than 80% of prescriptions are toric

How does NovaKone work?

1. NovaKone uses lens thickness to neutralize corneal irregularity
2. The NovaKone optical design is then employed to correct for normal spherical and astigmatic refractive errors
3. Dual Elliptical Stabilization™ and precision Rx manufacturing ensure a stable precise Rx lens

Step 1

Select Initial Base Curve

AVERAGE K	BASE CURVE	FITTING CURVE
41.00 to 42.99	8.6	8.6
43.00 to 46.99	8.2	8.6
47.00 to 49.99	7.8	8.4
50.00 to 52.99	7.4	8.4
53.00 to 55.99	7.0	8.2
56.00 to 58.99	6.6	8.2
59.00 to 61.99	6.2	8.2
62.00 to 64.99	5.8	7.8
65.00 to 67.99	5.4	7.8

Average K for CENTRAL 3 to 4 mm ONLY

Base Curve Verification

Custom SCL for Keratoconus

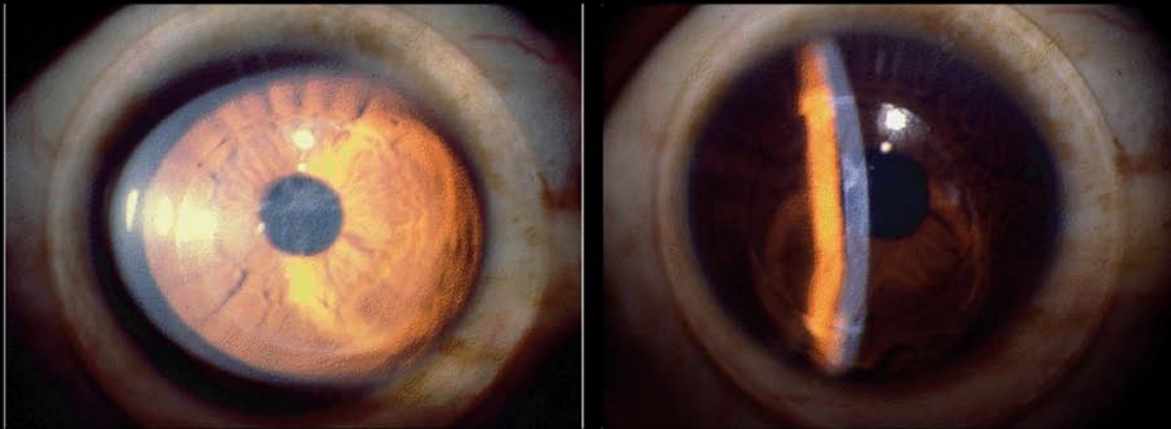
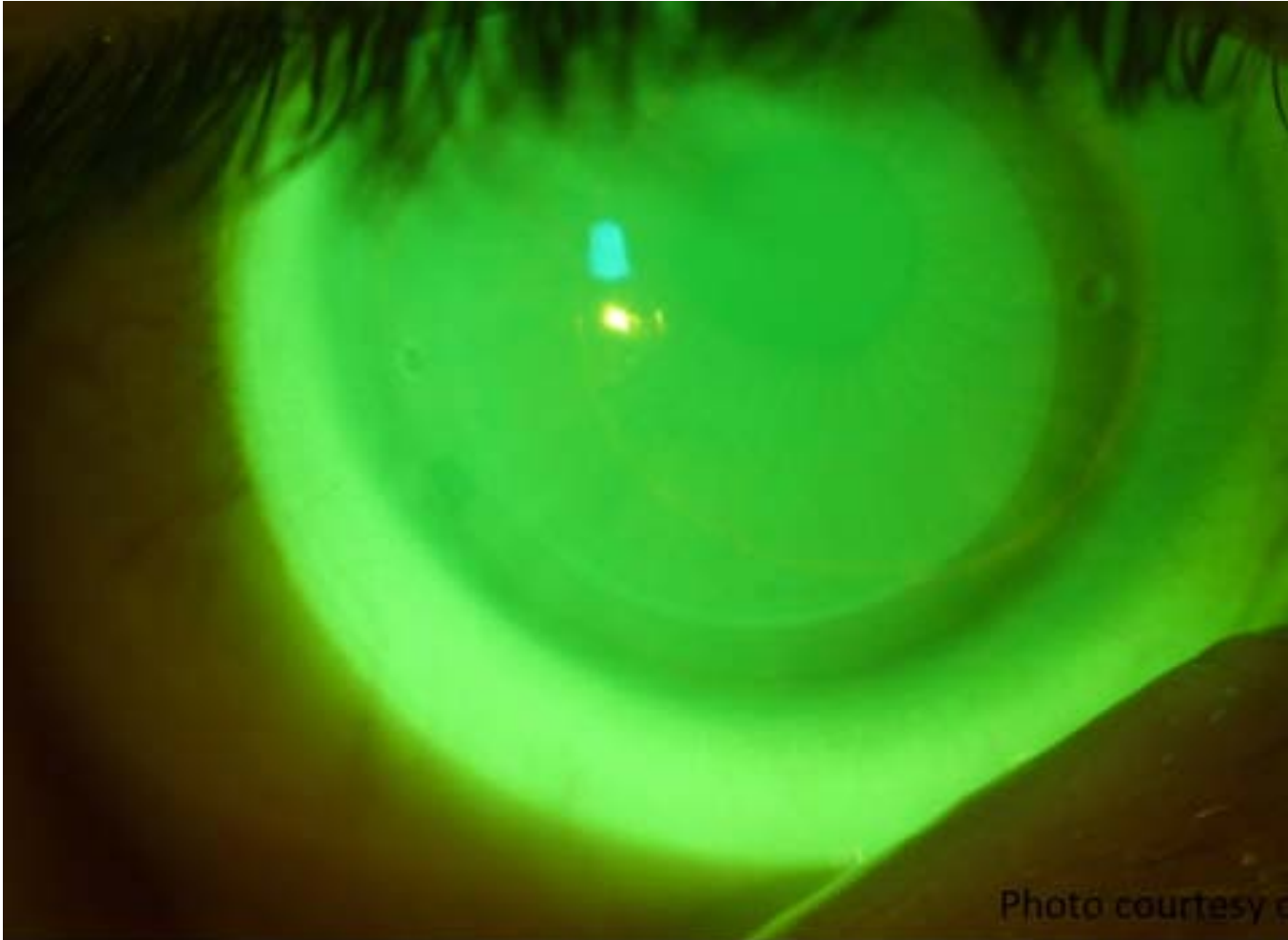

Photo courtesy of Mark Andre, FCLSA, Pacific University

An Ideal base curve should yield light central touch and stable optical findings

High Molecular NaFl



Step 2

The IT Factor

- IT = “Index of Thickness”, ranges from 0 to 4.
- Use the lowest IT factor possible
- The more irregular the cornea the higher the IT Factor should be to optimize visual acuity
- Verify IT factor with Keratometry or Topography over the lens. If any irregularities are observed, increase the IT Factor to improve optical stability.

Mire Evaluation

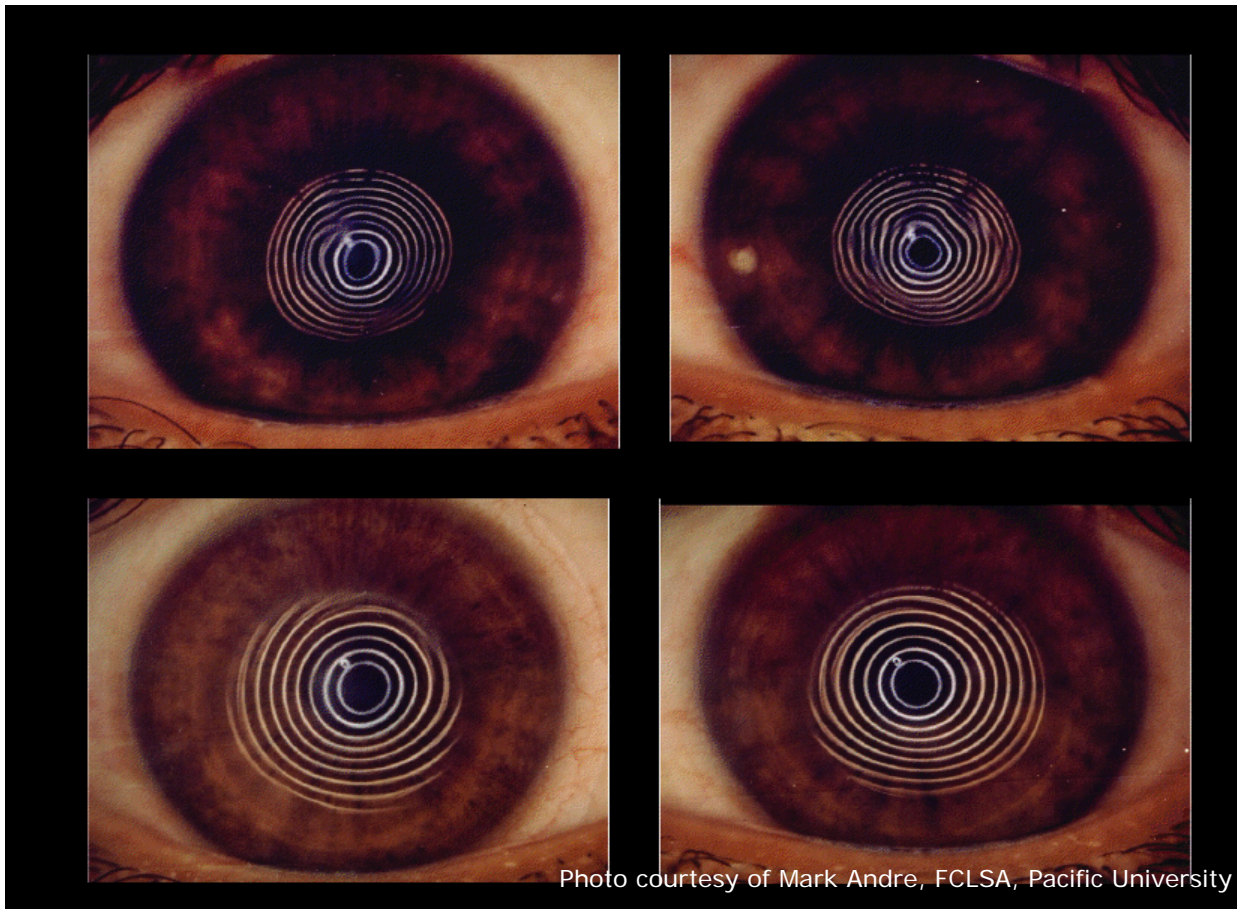


Photo courtesy of Mark Andre, FCLSA, Pacific University

Keratometric mires over the NovaKone lens will be crisp and clear with the proper IT factor

Step 3

Determine Lens Power

- Over refract and calculate the power of the Rx lens
- Compensate for rotation
 - All Dx lenses have Dual Elliptical Stabilization to assess rotation
 - Dx lenses have no actual cylinder power

Step 4

The Fitting Curve

- Able to select the base curve, IT factor, and lens power. Given any base curve, the Dx lens will only have a single fitting curve from the fitting set.
- Evaluate initial lens in order to determine if the fitting curve on the diagnostic lens is appropriate or needs to be altered on the prescription lens order.

Step 4

The Fitting Curve

The fitting curve should demonstrate typical fitting characteristics of a standard soft lens fit.

- If the fitting curve is too flat there will be excessive movement and / or edge lift (order steeper fitting curve)
- Little or no movement and / or edge impingement would indicate the fit curve is too steep (order flatter fitting curve)
- Alden labels the fitting curve with the actual radius in millimeter, practitioners should be comfortable with these values in relationship to a “good” lens fit.
 - The fitting curve should be adjusted in a minimum of 0.2mm increments

Glasses

- Early keratoconus
- Patient convenience
- Use for cylinder correction in conjunction with contact lenses correcting the sphere



Piggyback Lenses: Indications

- Soft lens under RGP lens
- Poor comfort / movement with RGP lenses
- Epithelial defects with RGP lenses
- Apical nodules
- Epithelial Basement Membrane Dystrophy

Piggyback Fitting Principles

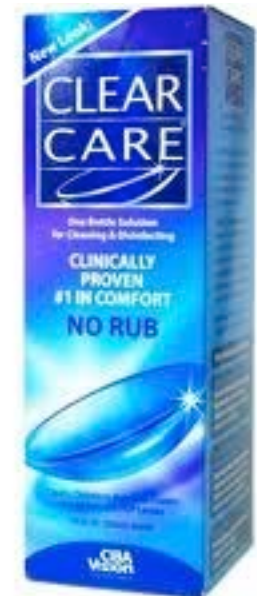- Improved GP and soft lens materials provide better oxygen permeability and prevent corneal edema and hypoxia
- Use high DK RGP lens and silicone hydrogel soft lenses
- Success with Proclear 1 day and 1 day- Acuvue Tru Eye soft lenses
- Plus powered soft lens - flatten the RGP fit
- Minus powered soft lens - steepen the RGP fit

Advantages

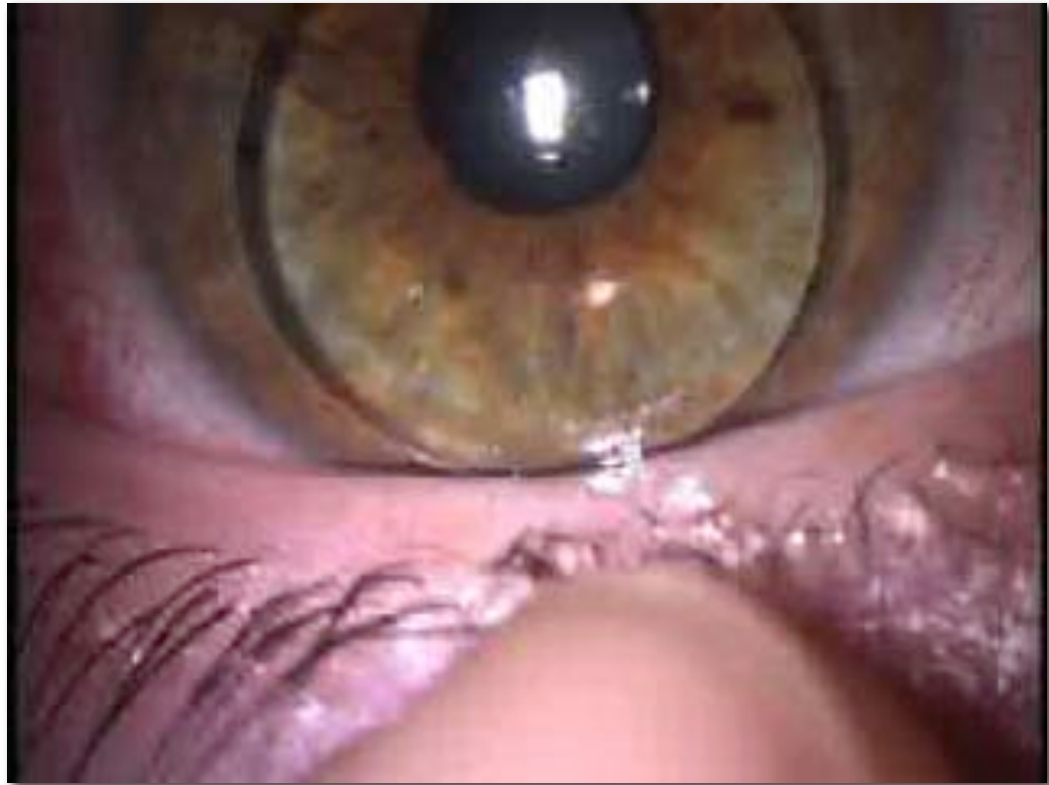- Better comfort than standard RGP CL
 - No corneal compromise or complications
 - No hypoxia
 - Improved comfort compared with RGP lens alone
 - Same or increased wearing time vs. the RGP lens worn alone
 - Same or better visual acuity
-
- Study by Jill J. Rodio-Vivadelli, OD, FAAO, & Ralph Gundel, OD, FAAO Sept 2006

Disadvantages

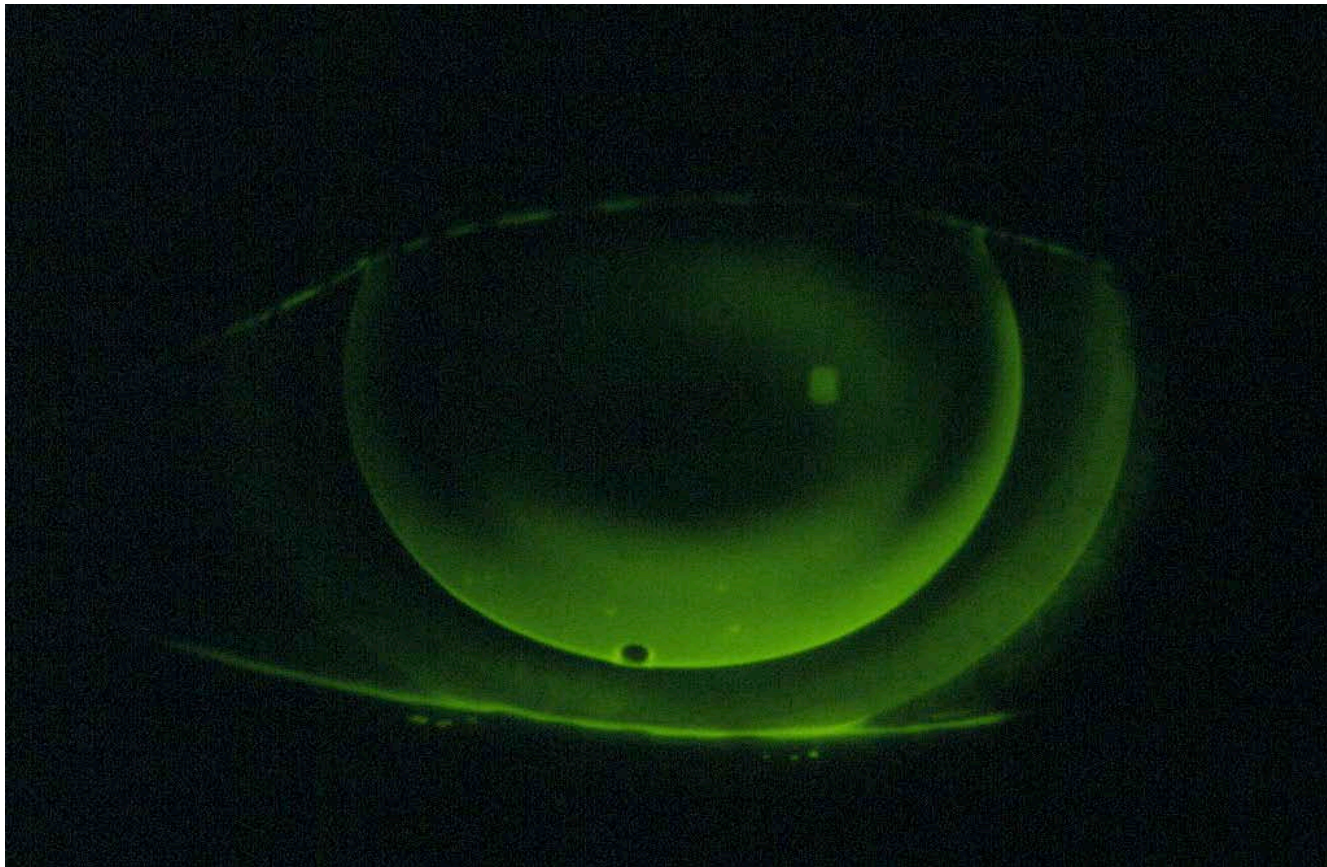
- More difficulty and inconvenience with piggyback lens system
- Loss of GP lens
- Damage to soft lens
- Multiple lens care systems



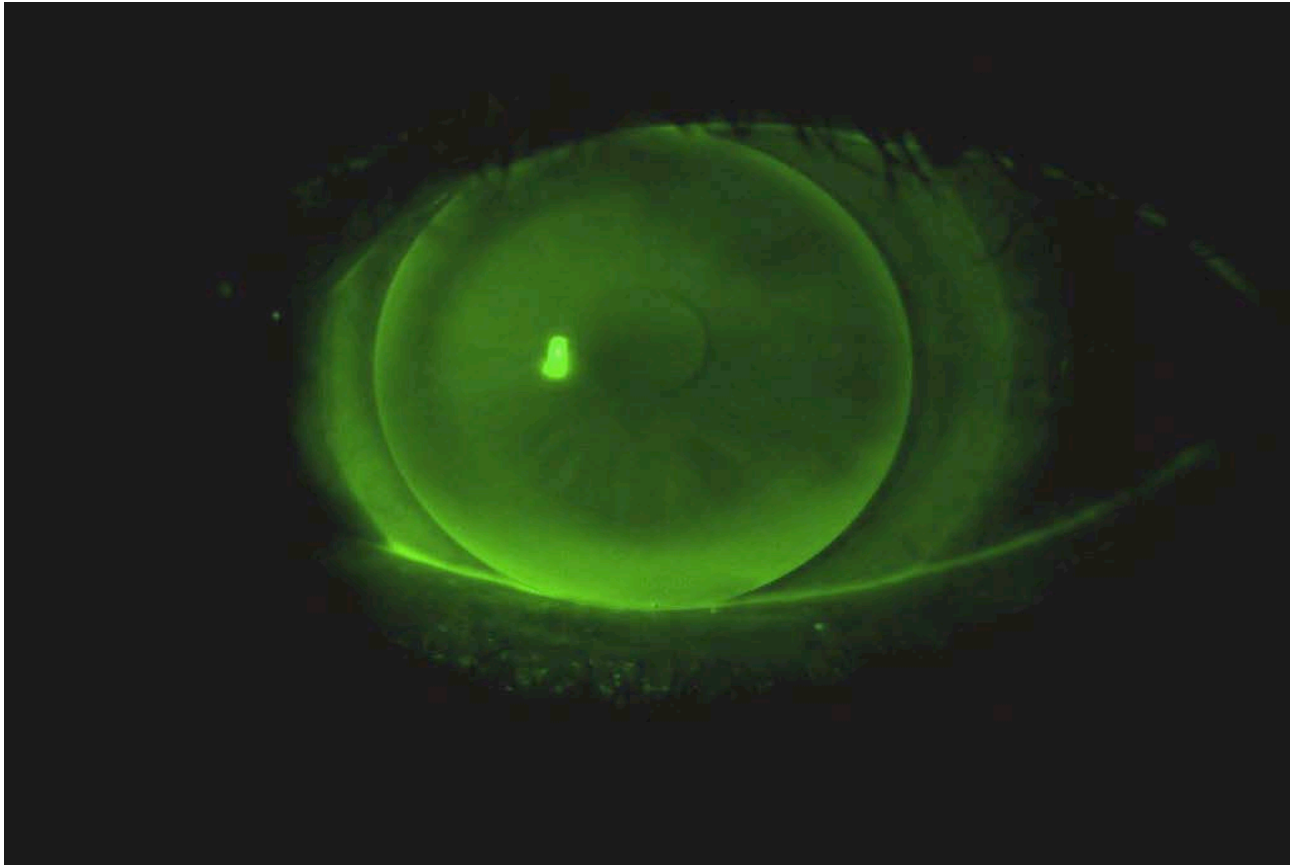
Piggyback lens



Piggyback Lens - flat fit



Piggyback Lens - optimal fit



Hybrid Lenses - SynergEyes

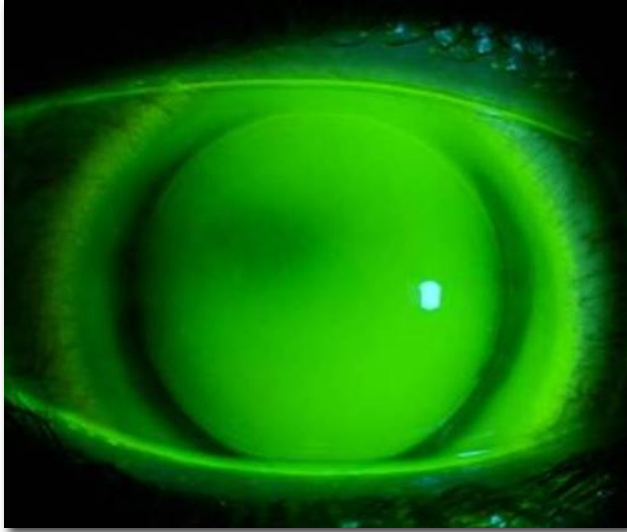
- Rigid center
- Soft skirt
- Adjustable central base curve and skirt curvature

Hybrid lenses - SynergEyes

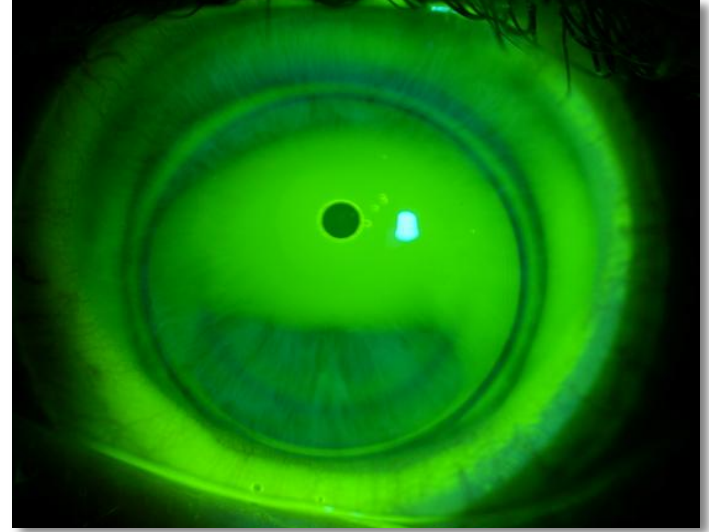- SynergEyes A lens design
 - Early or moderate keratoconus
 - Normal corneas
- SynergEyes KC lens design
 - More advanced keratoconus
- Poor centration, stability and / or wearing time with RGP lenses
- RGP lens intolerance

SynergEyes Fitting

- Apical clearance over central cornea with little or no touch in GP part of lens
- No bubbles in central part of lens
- Light touch at rigid / soft junction
- Landing in soft skirt
- Alignment under soft skirt
- Lens free to move on lid push up



Apical clearance
(note landing)



Insufficient clearance

Advantages

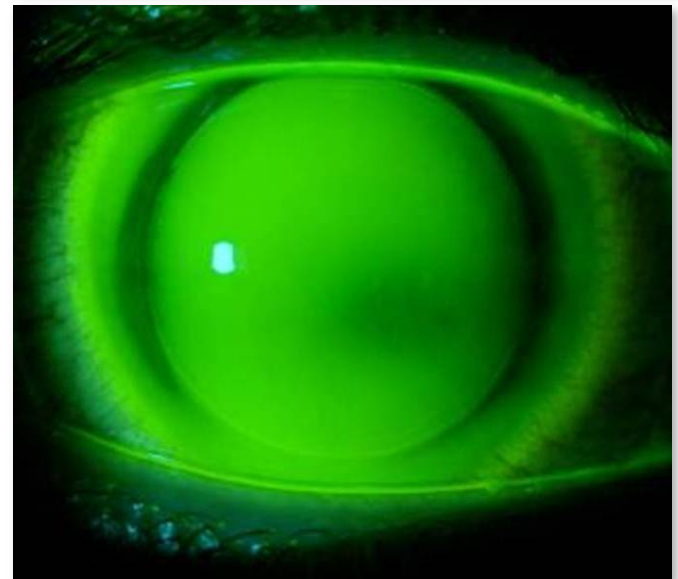
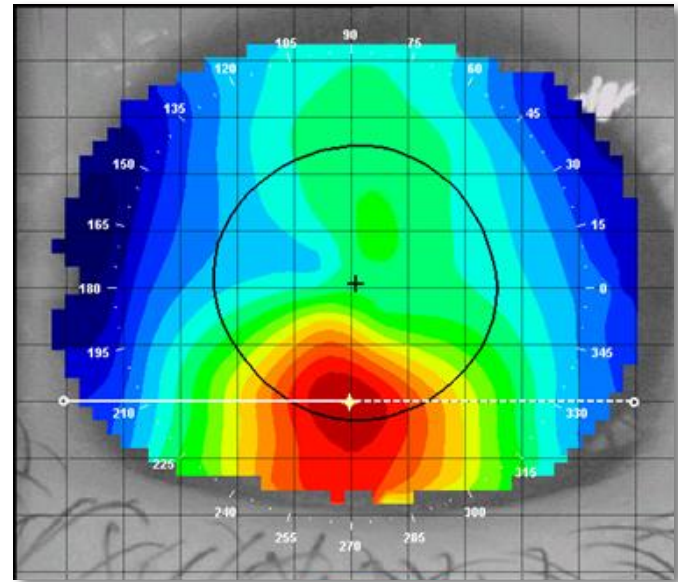
- Good vision
- Good lens centration
- Higher oxygen permeability centrally (and soon in periphery)
- Increased fitting parameters for base curve and power
- Various peripheral curve systems

Disadvantages

- Lens tightening
- Need high-molecular-weight fluorescein to evaluate the fit

SynergEyes A

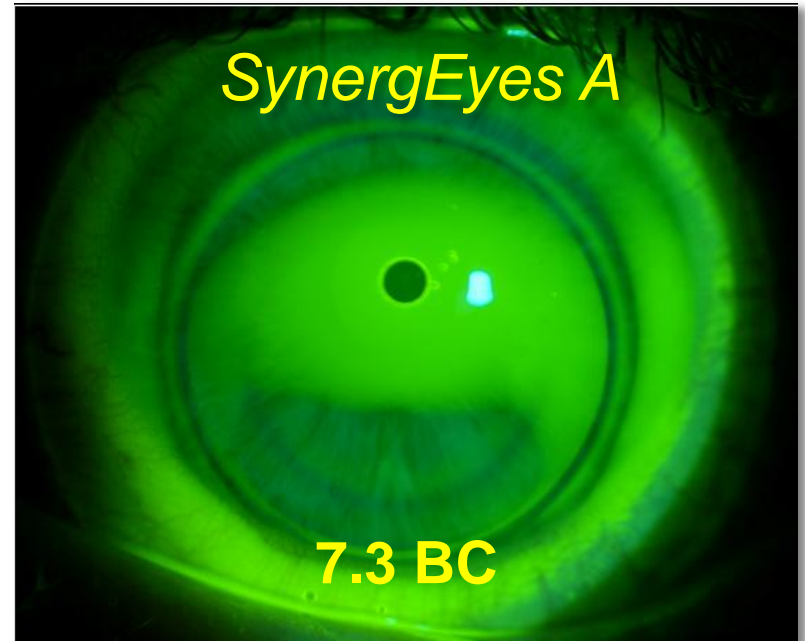
- Emerging or moderate keratoconus
- Acceptable fit
- Central clearance with minimal touch



Picture courtesy of Erin Clark, SynergEyes

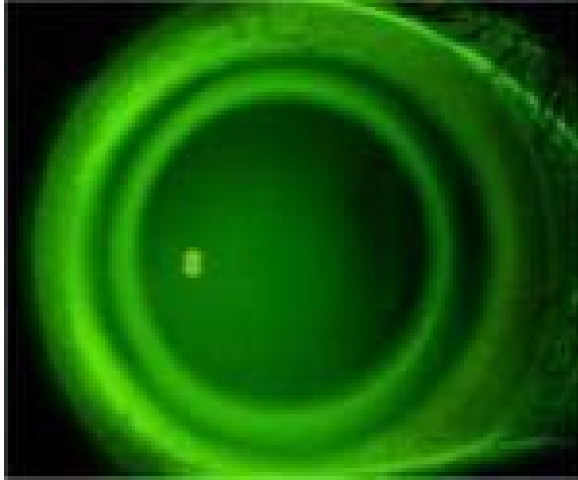SynergEyes A

- Unacceptable fit
- Central bubble, inferior touch
- Consider SynergEyes KC lens design

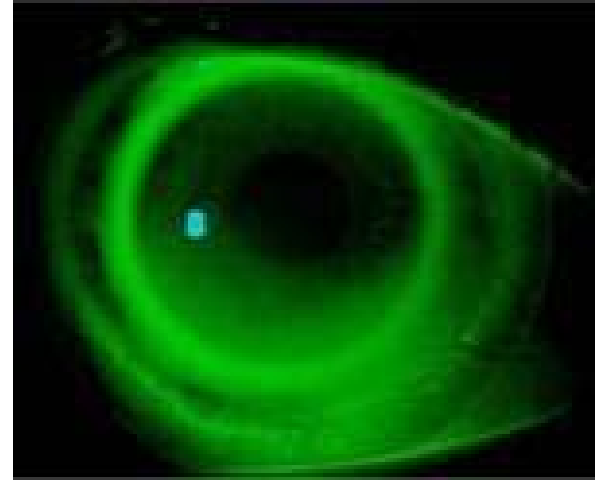


Picture courtesy of Erin Clark, SynergEyes

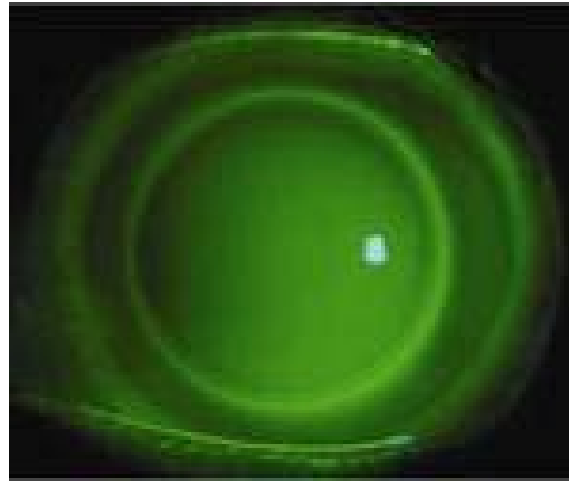
SynergEyes A



Minimal apical clearance



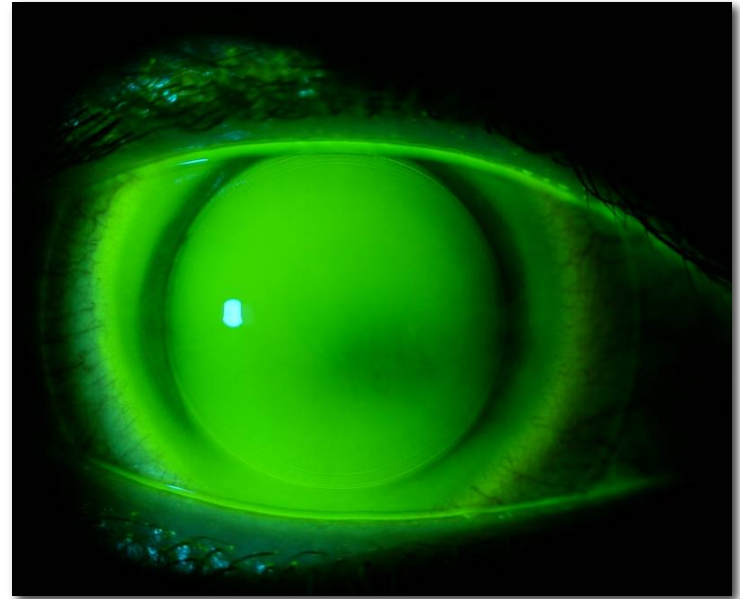
Apical touch



Ideal apical clearance

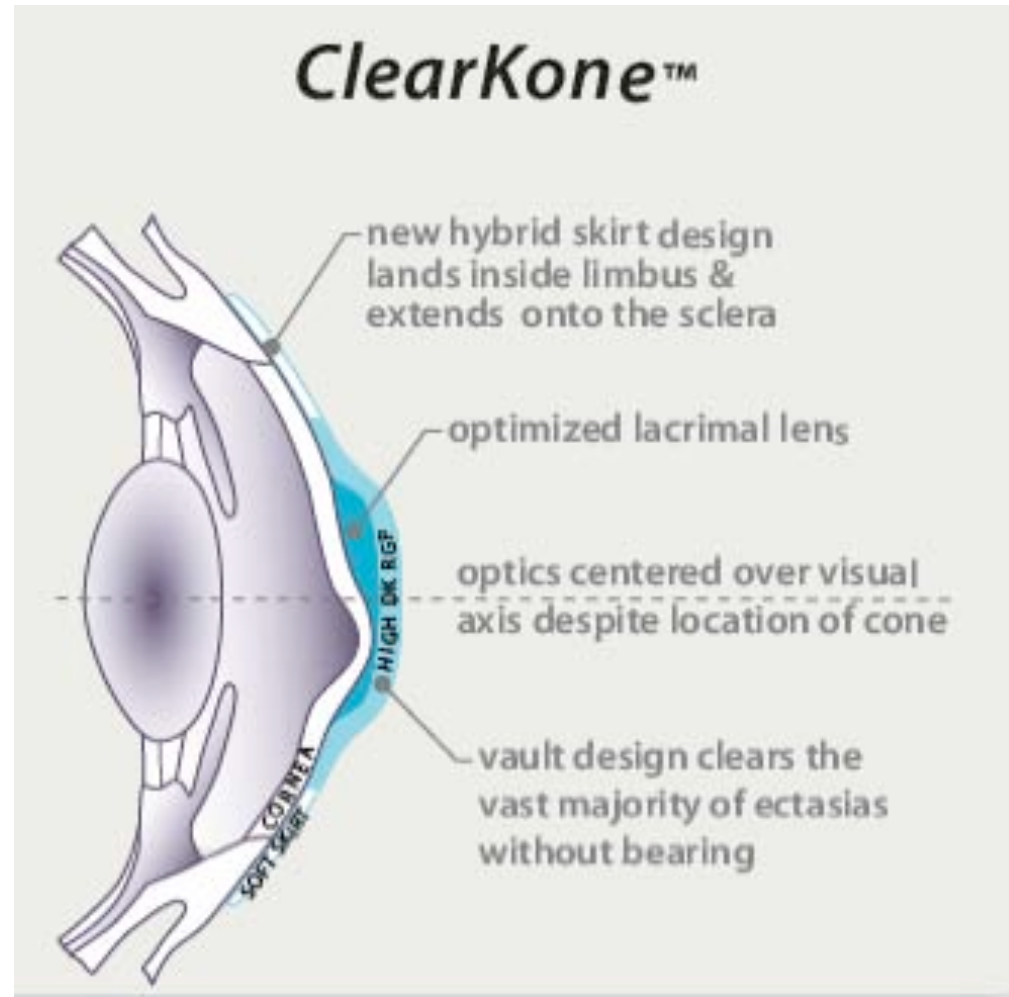
SynergEyes KC

- Ideal fit
- Apical clearance
- Soft landing where base curve meets skirt curve
- Minimal touch in rigid portion



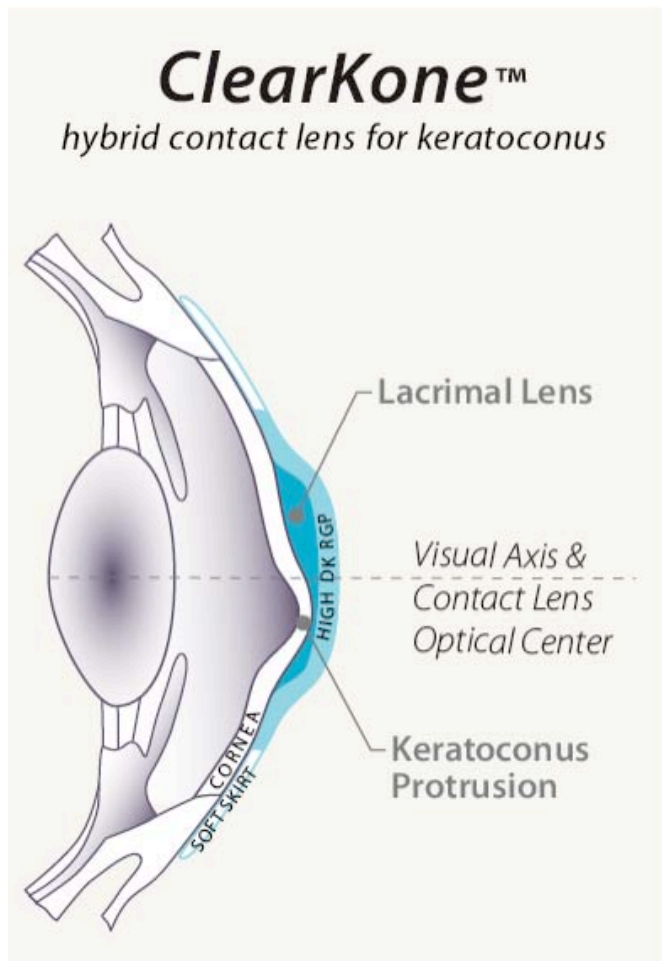
Picture courtesy of Erin Clark, SynergEyes

SynergEyes ClearKone

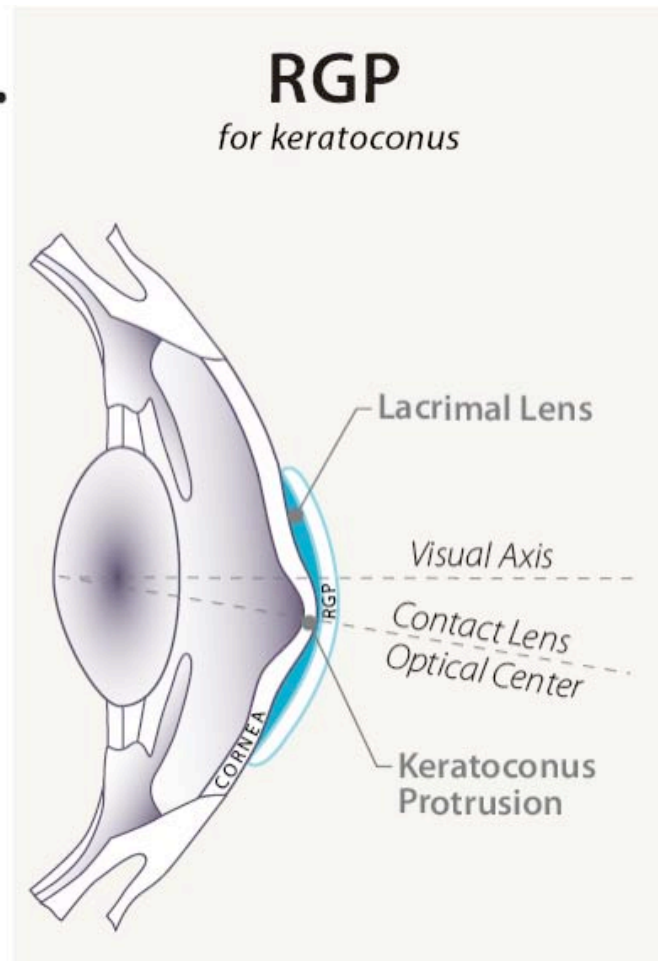


- The vault value describes the overall relative depth of the lens on the cornea.
- The end point of the fitting is the least amount of vault needed to clear the cone.
- Design gives the ability to “vault” over the vast majority of ectasias without bearing

Unlike RGPs, hybrid platform centers optics independent of the location of the cone



vs.



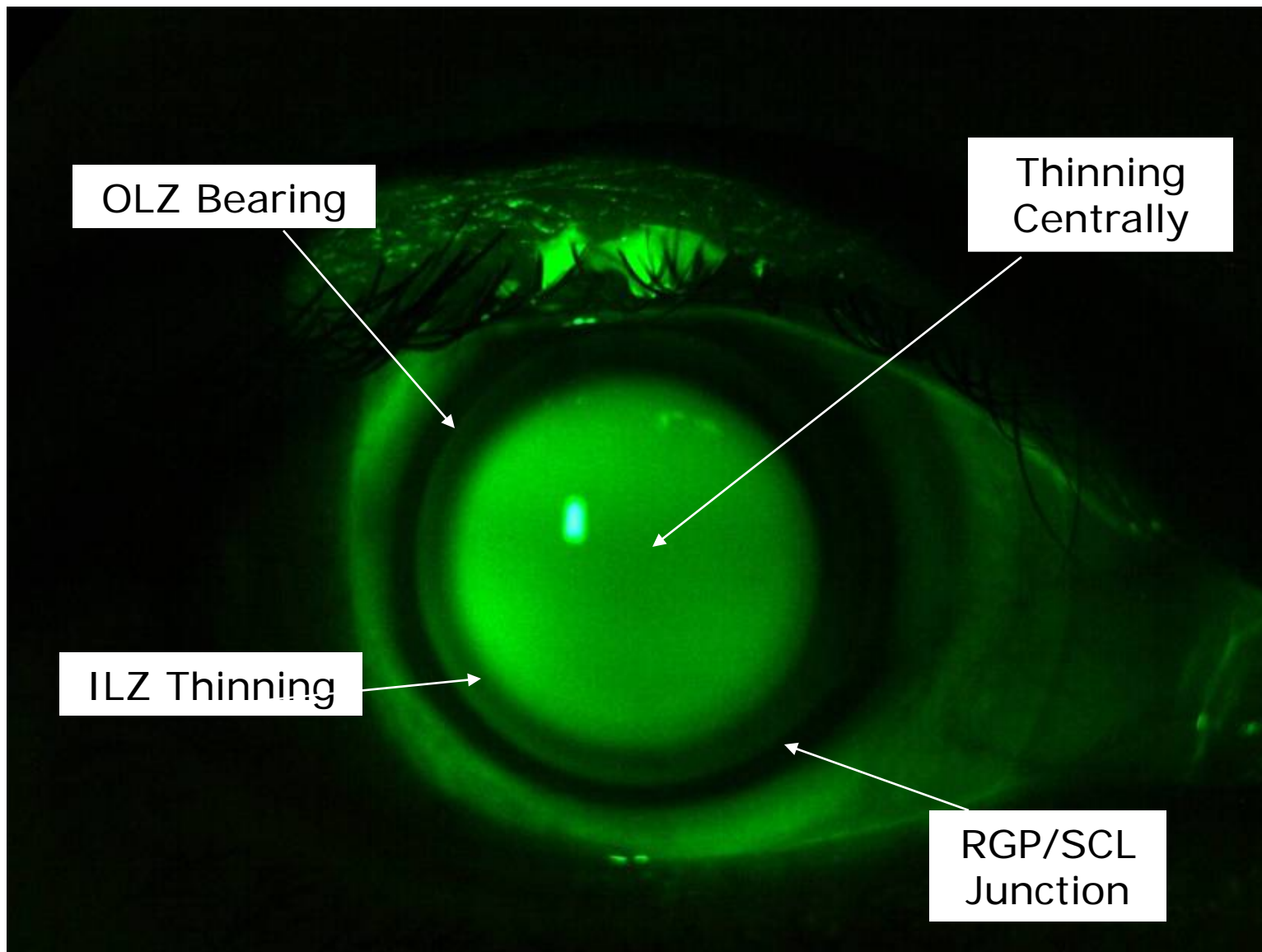
- Vault
 - The vault value describes the overall relative depth of the lens
- Outer Landing Zone (OLZ)
 - Portion of the lens that lands on the soft material
- Inner Landing Zone (ILZ)
 - Portion of the lens that lands on the RGP material

SynergEyes ClearKone

- Oval / nipple KCN (moderate to advanced)
- Central and the majority of decentered cones
- Post RK, PRK, Lasik induced ectasia
- May be able to fit Globus, PMD and irregular corneas

SynergEyes ClearKone

- Disadvantages
- May not be able to fit the following:
- Ectasia that extends beyond landing zone
- Highly irregular or asymmetric landing pattern (seen with advanced PMD)



Ideal ClearKone Fit

Barbara, 77 year old Caucasian Female

- S/P PK, AK, AC IOL OU
- S/P Lasik OS
- H/o KCN OU

1/2008 fit with bitoric lens OD

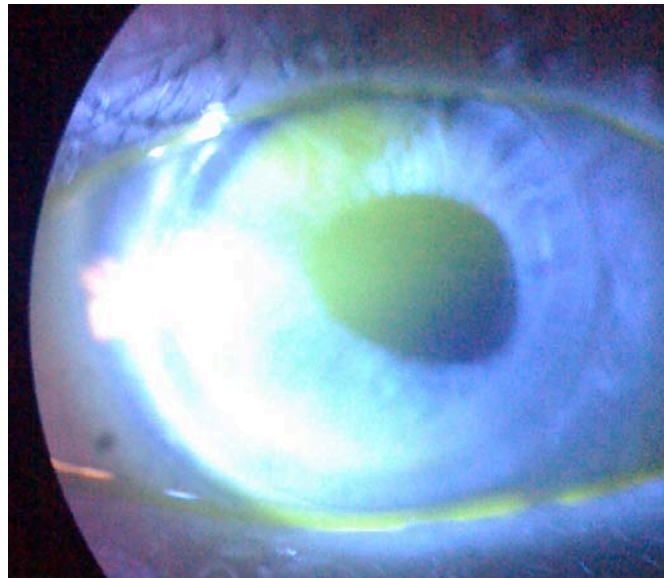
VA: 20/25

poor comfort

High astigmatism OU (6D on topography)

Barbara

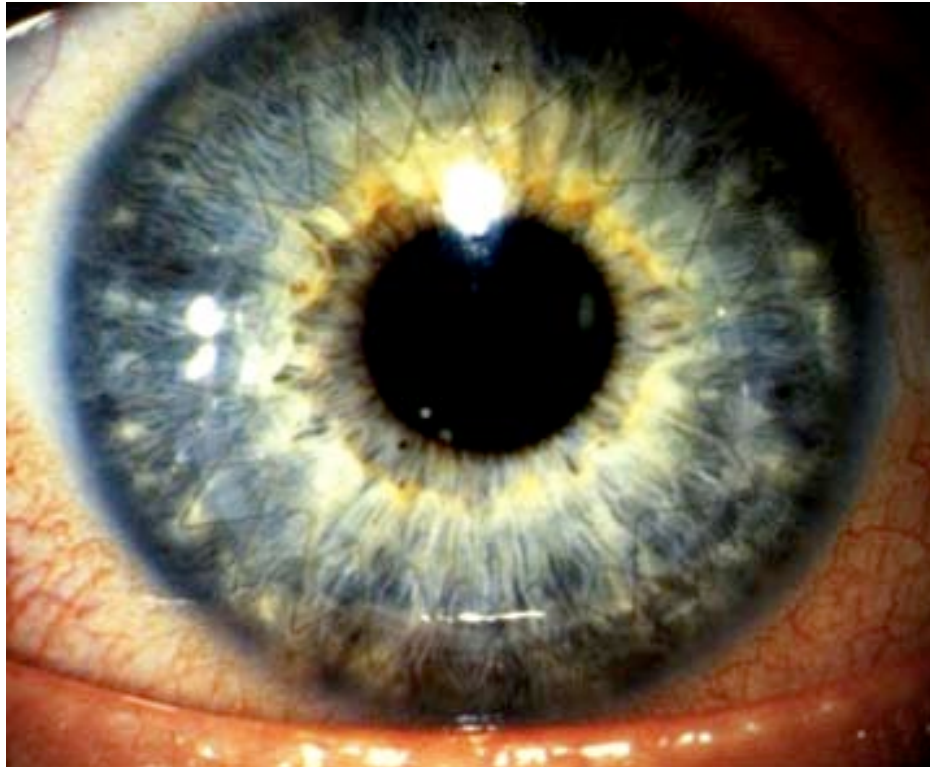- 7/2009 refit to Clear Kone OD
- Clear Kone Vault 250 / -1.25 / medium skirt
- 20/20-1
- Great comfort, can not feel lens at all



Barbara fit continued

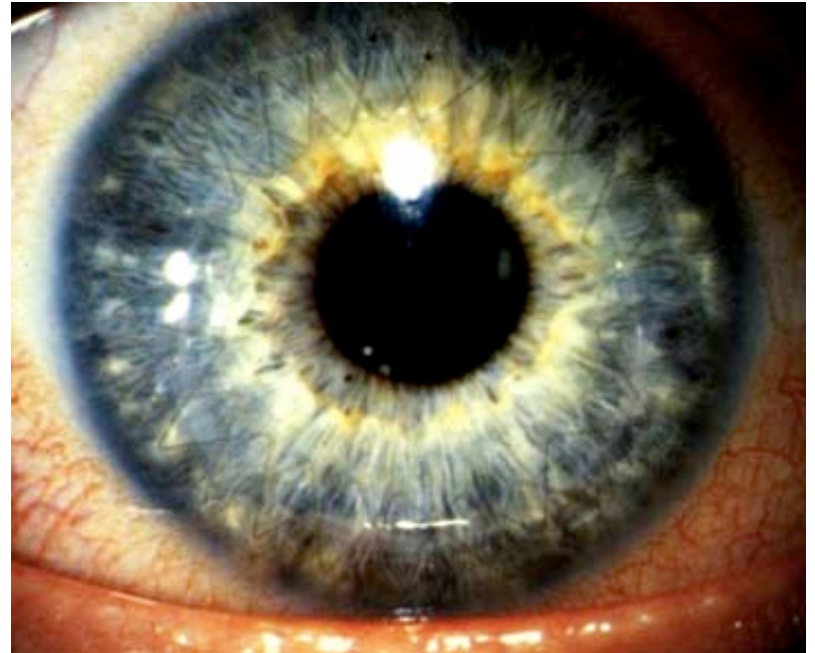
- 3/2010 Post multiple retinal surgeries and now ready for contact lens OS
- Uncorrected VA OS 20/400
- Fit with Clear Kone VLT 350 / -7.75 / medium
- VA improved to 20/150+1
- Good vision, helps a lot with driving and reading

Surgical treatment options for keratoconus



Surgical treatment options for keratoconus

- Penetrating keratoplasty
 - ~10-20% of KCN patients will require a PKP in their lifetime
 - Long-term complications of PKP

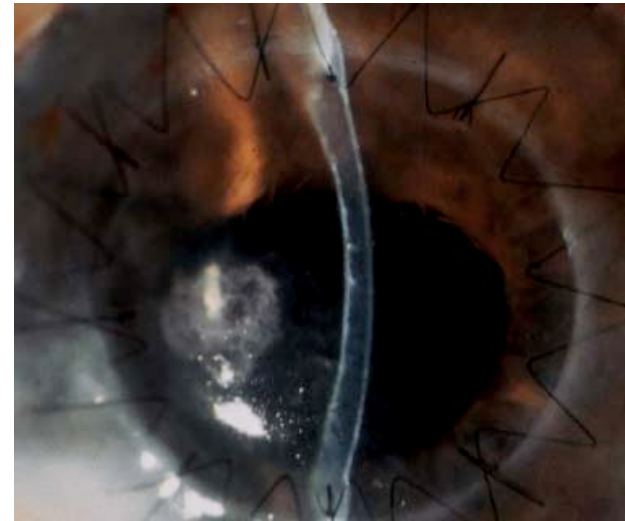


Surgical treatment options for keratoconus

- Penetrating keratoplasty
 - 20-30% of patients develop immunologic rejection
 - ~ 14-29% long-term graft failure rate

Surgical treatment options for keratoconus

- Deep Anterior Lamellar Keratoplasty (DALK)
 - The concept of lamellar keratoplasty to remove the risk of endothelial rejection has been around for over 150 years
 - Dissecting near Descemet's membrane was first attempted in the late 1950s
 - Pathological stroma is completely removed
 - Less interface opacity than prior LKP
 - Visual acuity comparable to PKP



Deep Anterior Lamellar Keratoplasty (DALK)

- Direct Open Dissection
 - Stroma removed layer by layer until clear stroma remains or Descemet's Membrane is exposed
 - HOWEVER, rate of intraoperative perforation is high >30-35% and frequently, the surgeon fails to bare Descemet's
 - Difficult to visualize depth of dissection relative to corneal thickness during surgery
 - Difficult to tell small differences in refractive index between the corneal tissue and aqueous

Deep Anterior Lamellar Keratoplasty (DALK)

- Hydrodelamination
 - Cornea is trephined to ~ 75% depth.
 - Hydrodelamination. Small pocket made in central stroma and BSS injected with a blunt 27-gauge cannula.
The solution penetrates

swell.



Deep Anterior Lamellar Keratoplasty (DALK)

- Hydrodelamination continued
 - Spatula delamination.
 - A fine spatula is inserted into the hydrodelaminated stroma to remove the stroma layer by layer.
 - Finally, Descemet's membrane is exposed.

- Study by Sugita et al.
- Descemet's punctured intraoperatively 39.2%
- However, no significant differences in VA when Descemet's is punctured.

DALK:

Advantages and Disadvantages

- Advantages of DALK over LKP
 - Smooth donor-to-recipient interface
 - Reduced risk of interface scarring
 - Identical level of dissection depth between donor and recipient tissues

DALK:

Advantages and Disadvantages

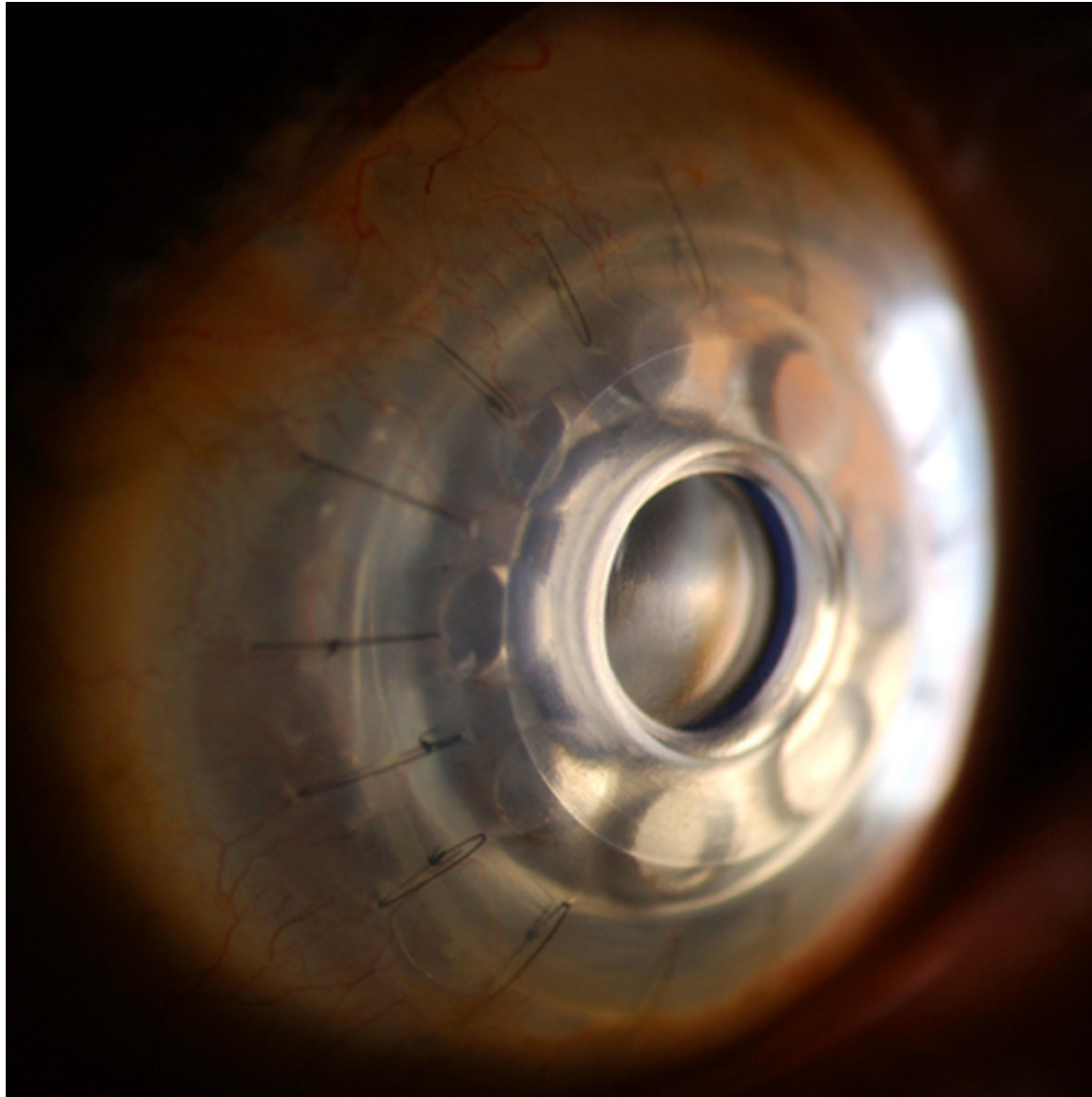
- Advantages of DALK over PKP
 - Fewer intraocular complications:
 - Endophthalmitis, glaucoma, anterior synechia, injury to lens and vitreous
 - Less risk of endothelial rejection (main cause of graft failure post PKP)
 - Faster rehabilitation; no long-term immunosuppression / steroids
 - Decreased risk of infection, glaucoma, and cataract
 - Superior wound strength
 - Fewer rigid criteria for donor corneal tissue selection

DALK:

Advantages and Disadvantages

- Disadvantages of DALK
 - Technically more difficult and time consuming
 - Cannot be performed in patients with prior disruption of Descemet's
 - Relatively high rate of intraoperative perforation of Descemet's
 - Still may have interface haze and night vision problems
 - Donor tissue may not be adequate should the need to convert to PKP arise intraoperatively

Keratoprosthetics



Keratoprosthetics

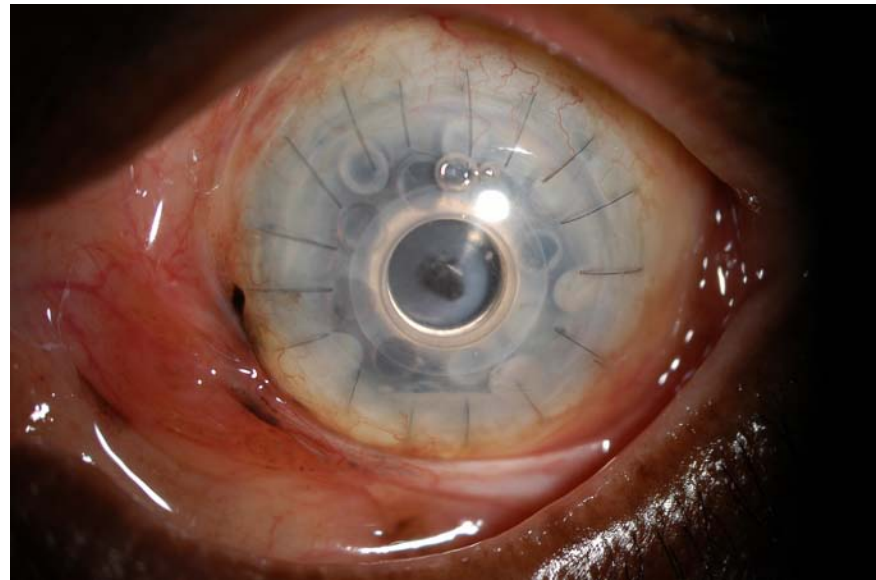
- Synthetic or partially synthetic device to replace an opaque human cornea in order to provide a clear view through the front of the eye.
- Surgical procedure where a severely damaged or diseased cornea is replaced with an artificial cornea.

Keratoprosthesis

- Used for severe corneal opacities.
- Failed corneal transplants.
- Used when standard corneal transplants are unlikely to succeed.

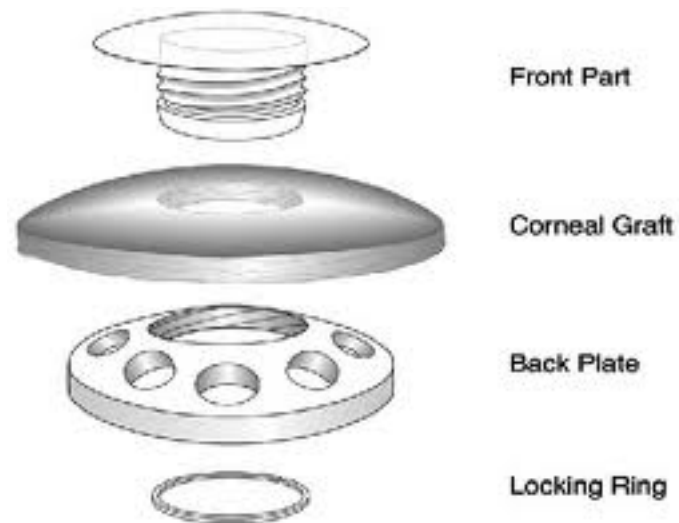
Keratoprosthetics

- Keratoprosthetics are made of clear plastic with excellent tissue tolerance and optical properties.
- Vary in design, size and implantation techniques.



Keratoprosthesis

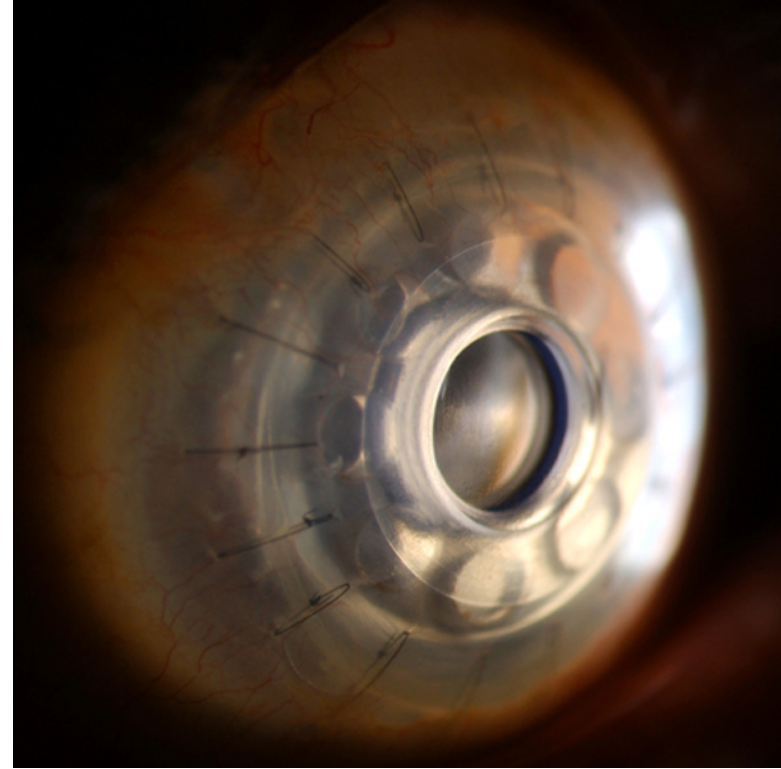
- Keratoprosthesis consists of three parts and when fully assembled has the shape of a collar-button.



Keratoprosthetics

- Two devices are approved for use in the United States.
- AlphaCor™
- Developed in Australia.

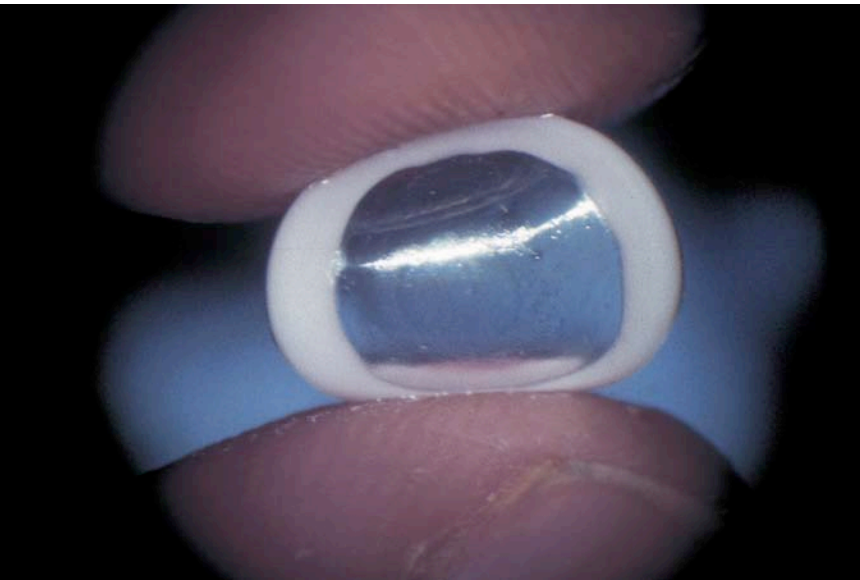Boston Keratoprosthesis (Kpro)



- Developed by Dr. Claes H. Dohlman, corneal specialist
- Under development since the 1960s.
- Received FDA clearance in 1992.

AlphaCor

- Made of a plastic-type material known as pHEMA.
- Consists of two parts
 1. A transparent low water content central core
 2. A cloudy high water content outer porous skirt

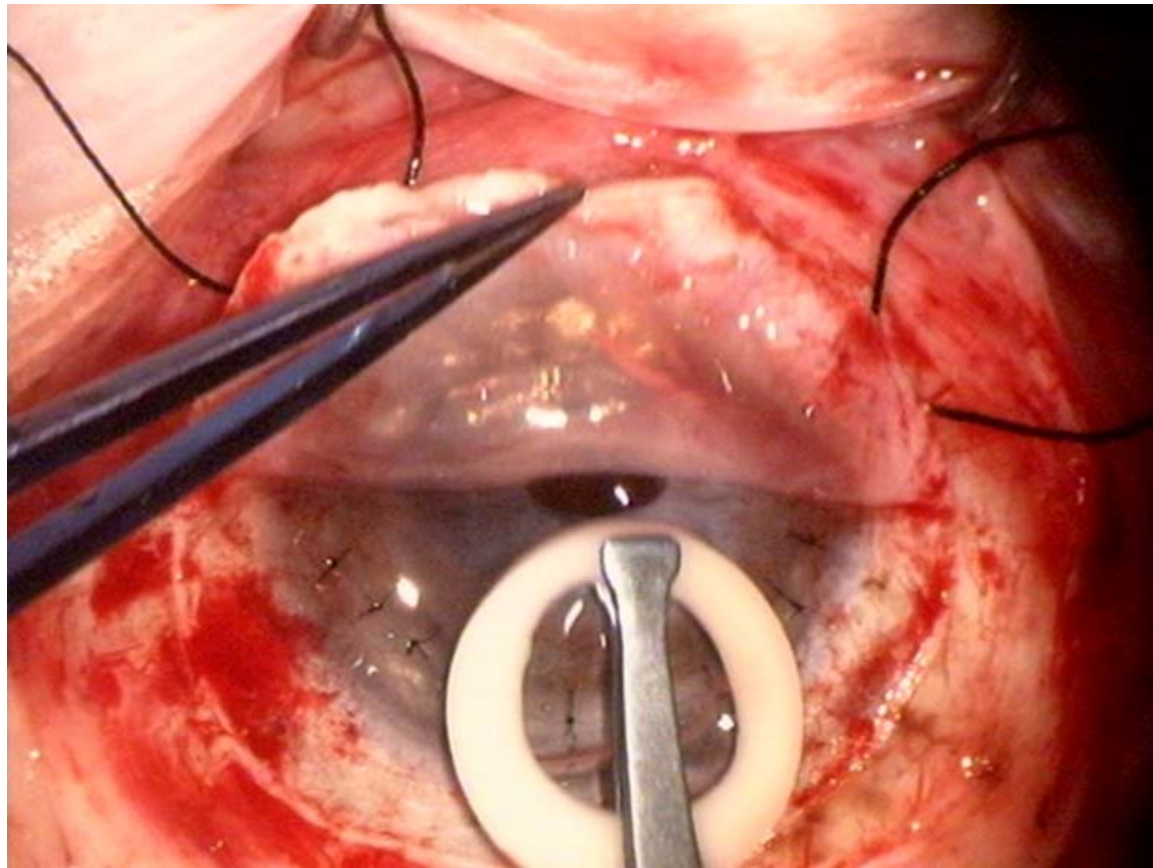


AlphaCor

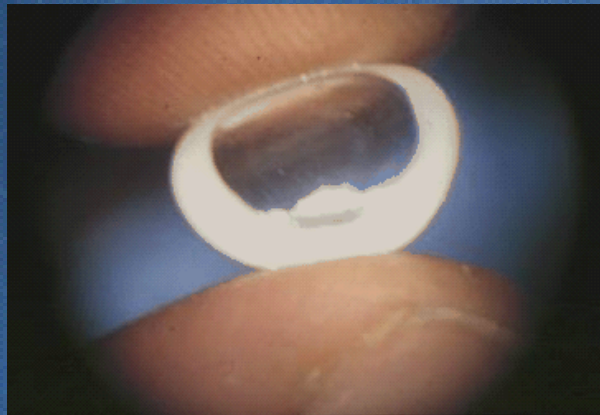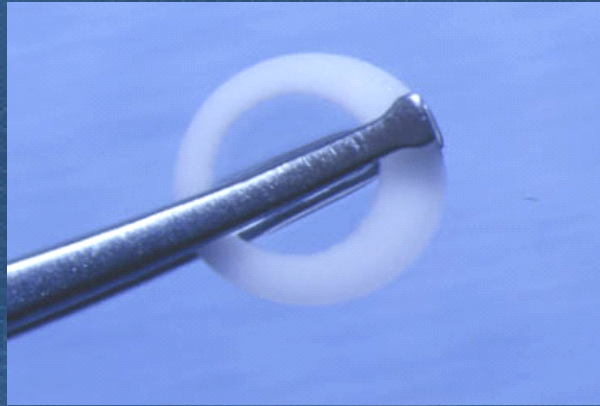
- AlphaCor procedure performed in two stages carried out approximately three months apart.
- First, a 180 degree incision is used to place the implant within the central portion of the diseased cornea.
- Then the outer conjunctiva is placed over the implant in order for the cornea to heal.

AlphaCor

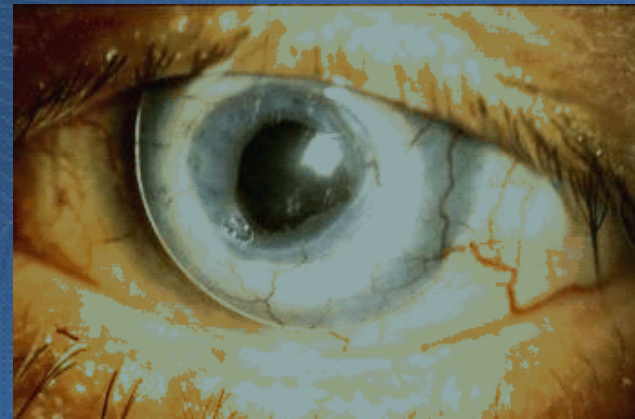
- Three months later, the outer half of the cornea is removed in order to provide a clear view into the eye.



AlphaCor Design

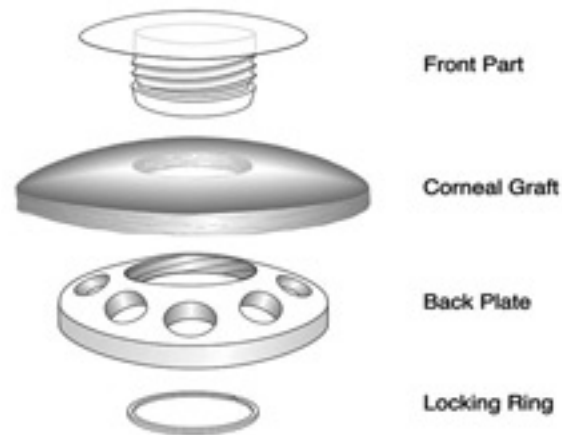


DPK & AlphaCor



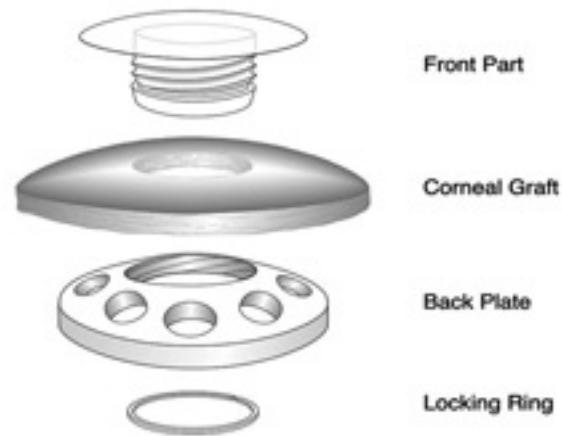
Kpro

- The most commonly used artificial cornea in the United States and in the world.
- It consists of three parts and when fully assembled, has the shape of a collar-button.



Kpro

- Consists of a central PMMA plastic button with a surrounding human donor corneal skirt.
- A back plate with porous holes sandwiches the inner human cornea.

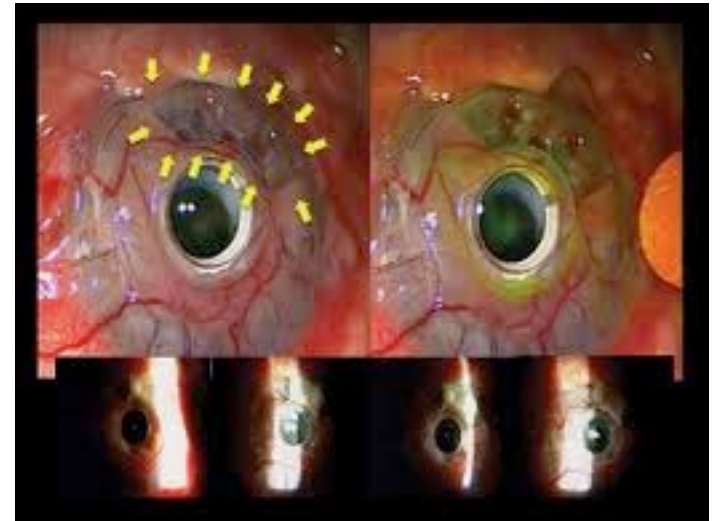


Kpro

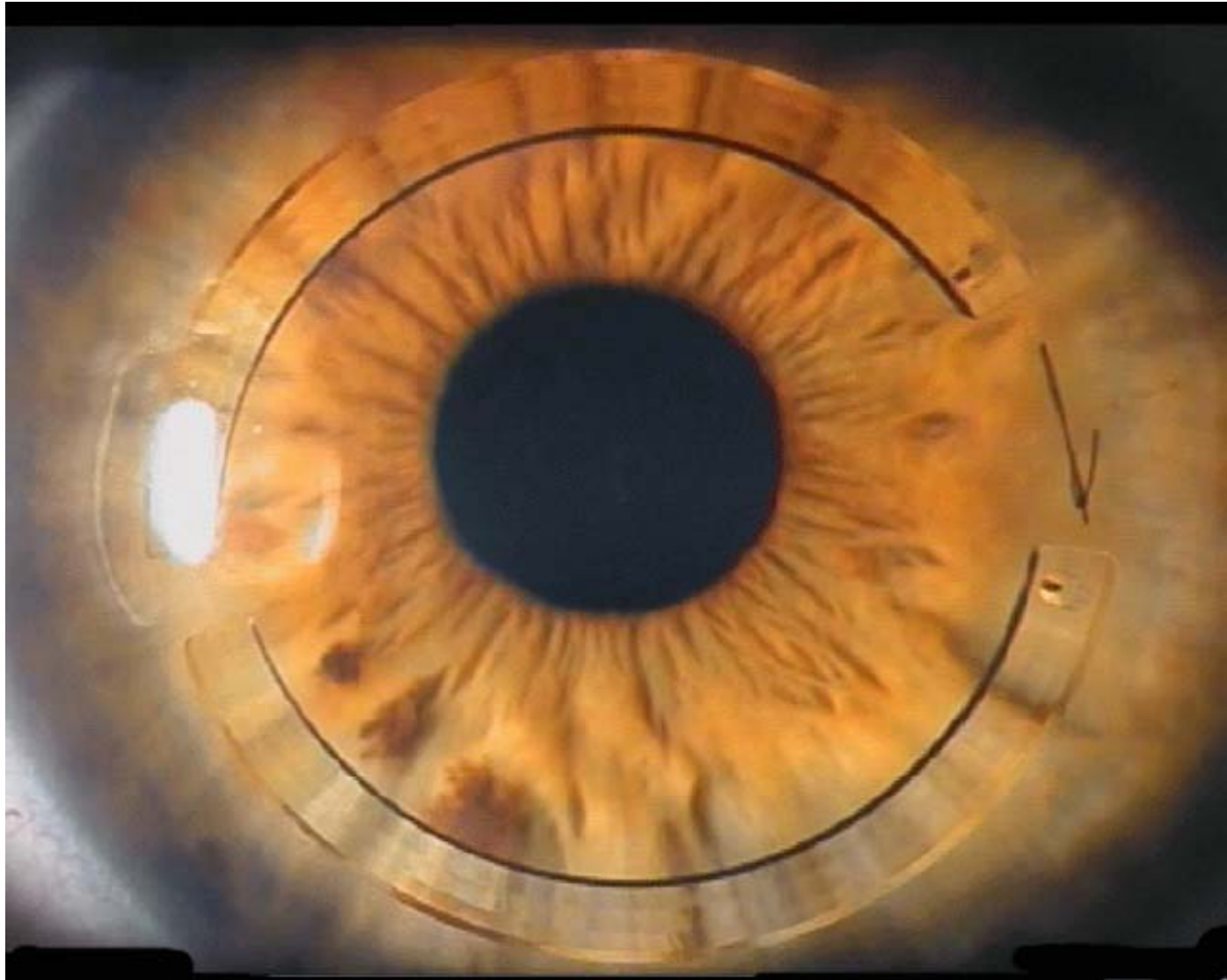
- Donor cornea is placed on the front collar button and a titanium screw locks the KPro device into proper alignment.
- Entire KPro procedure is done in a single procedure.
- If the eye is otherwise healthy, vision should return more rapidly than with the AlphaCor procedure.

Potential complications with Keratoprosthetics

- Infection
- Melting of the device
- Hemorrhage during surgery
- Worsening glaucoma
- Acute retinal necrosis
- Chronic hypotony
- Poor visual potential if the retina and optic nerve are unhealthy.

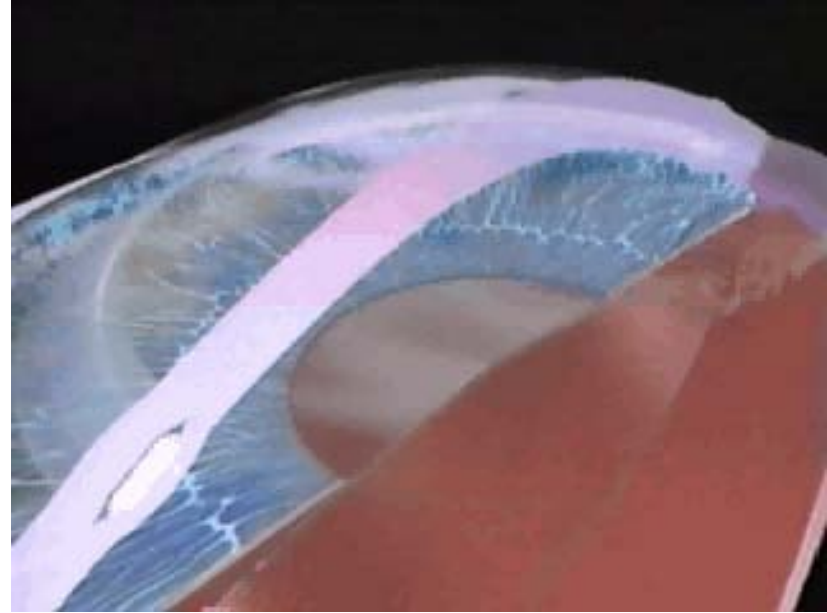


Intacs



Intrastromal Corneal Rings (ISCR)

- Arclike PMMA segments inserted into deep corneal stroma (~75% deep)
- Separate corneal lamella
- Shortens the arc length of the anterior corneal surface
- Flattens the central cornea
- Provides biomechanical support for thin ectatic corneas
- Increased flattening with thicker segments




Intrastromal Corneal Rings

- Two different rings available
 - In US since 2004, only INTACS are FDA approved to treat keratoconus in humans under surveillance of an IRB
 - 7 mm optical zone
 - Available sizes in the U.S.:
 - 0.25, 0.275, 0.30, 0.325, 0.35 mm
 - In Europe: 0.40 and 0.45 mm
 - Ferrara rings available outside U.S.
 - 4.5 to 5 mm optical zone



INTACS



Indications for INTACS

- Best indications for INTACS
- Mild to moderate keratoconus
- Clear optical zone
- Contact lens intolerant
- Maximum steepest K reading: 55 to 57 Diopters
- Corneal thickness at least 450 μm over area where INTACS will be placed



Indications for INTACS

- Other uses for INTACS
 - Low myopia
 - Post-LASIK ectasia
 - Pellucid marginal degeneration
 - Corneas too thin for additional enhancements after prior myopic LASIK



Goals of ISCR?

- Patient or clinician based?
- To eliminate need for glasses and contact lenses?
- To delay or avoid corneal grafts?
- To create a cornea more receptive to contact lenses?

INTACS studies

- **Boxer-Wachler (2003)**
- Ophthalmology. 2003; 110:1031-1040.
- 74 eyes
- Mean spherical equivalent decreased from -3.98D to -1.46D

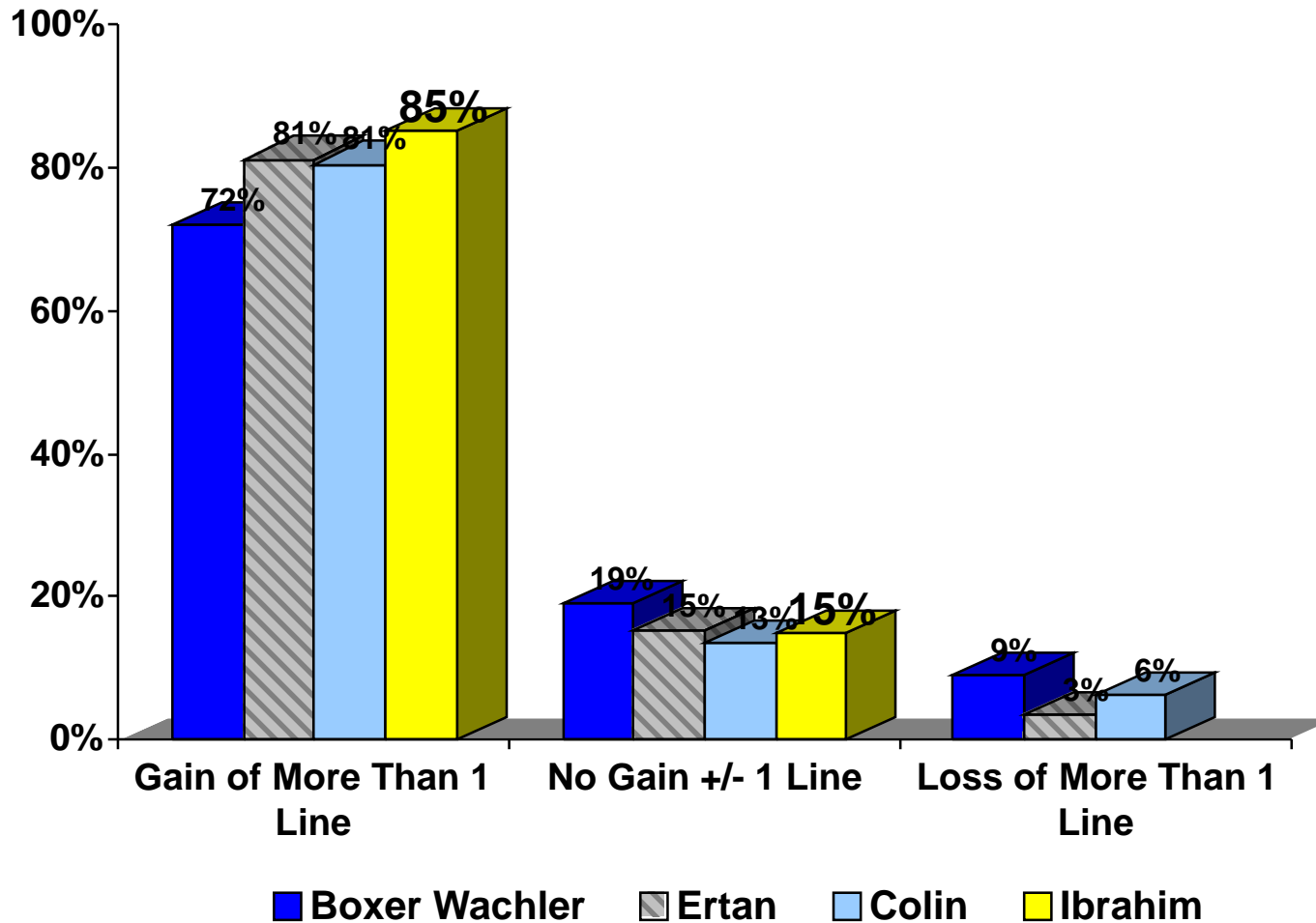
- **Ibrahim (2006)**
- Cataract & Refractive Surgery Today, Europe. 2006; 1:45-48.
- 186 Eyes
- 5 year follow-up
- Minimum simK readings decreased ~ 4.00D

INTACS studies

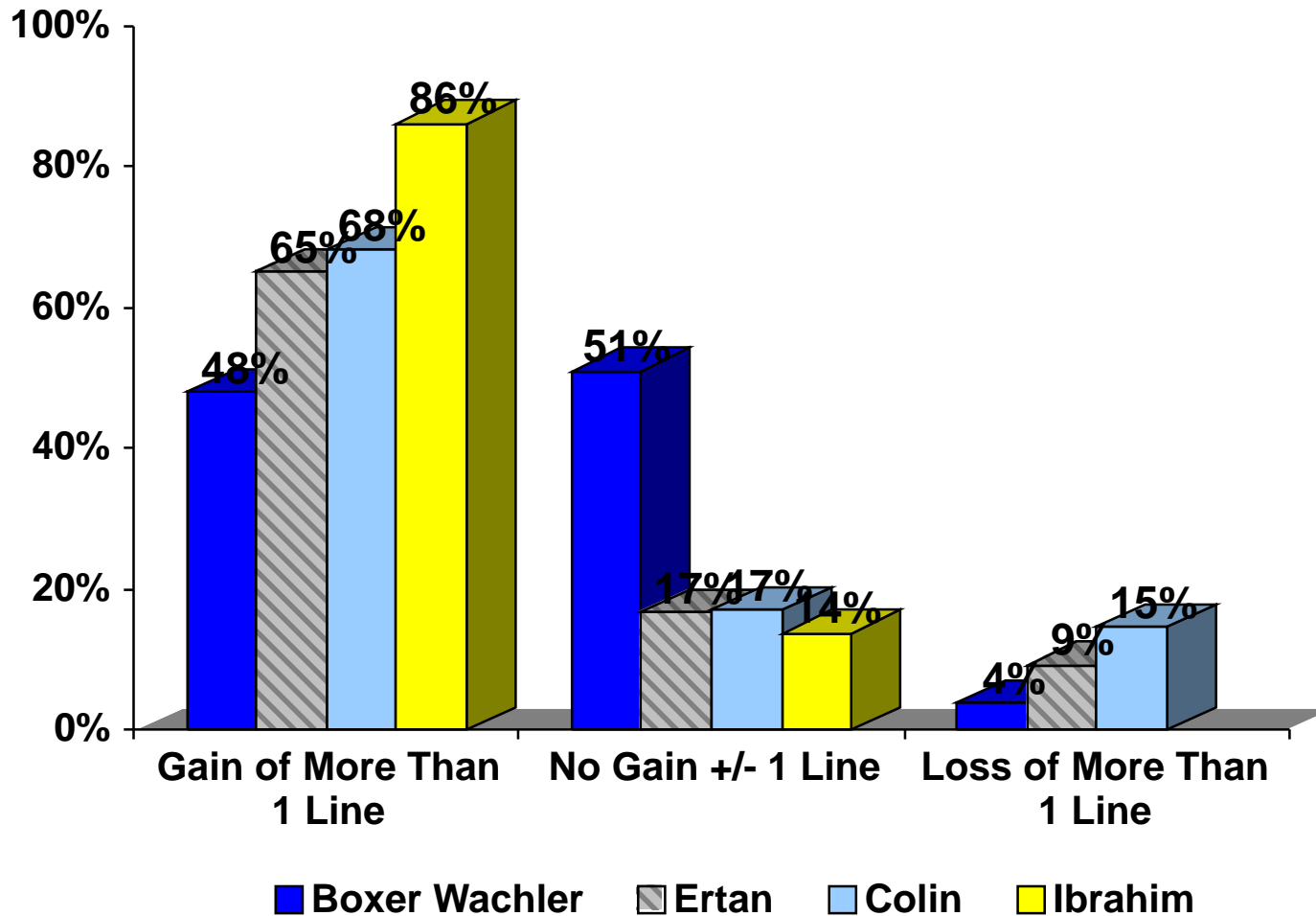
- **Ertan (2006)**
- Journal of Cataract and Refractive Surgery. 2006; 32:2039-2042.
- 118 Eyes
- 1 year follow-up
- Mean spherical equivalent decreased from -7.57D to -3.72D
- Mean keratometry decreased from 51.56D to 47.66D

- **Colin (2007)**
- Journal of Cataract and Refractive Surgery. 2007; 33:69-74.
- 100 Eyes
- 2 year follow-up
- Mean spherical equivalent decreased from -6.93D to -3.80D
- Mean keratometry decreased from 50.1D to 46.8D

INTACS - changes in UCVA



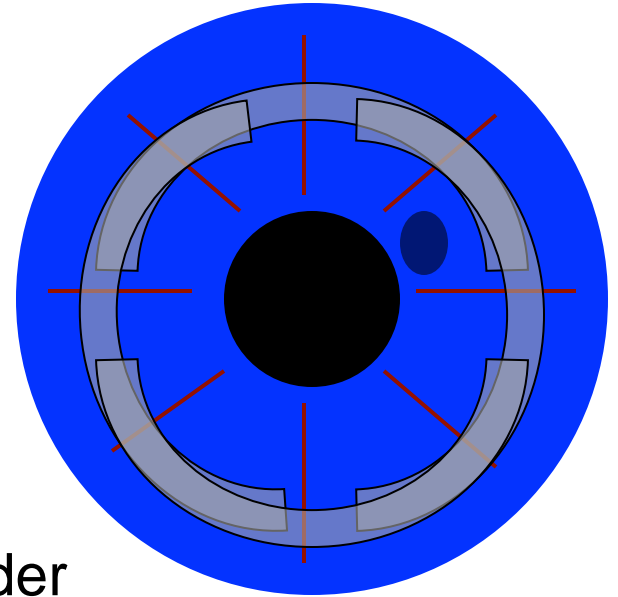
INTACS - changes in BCVA



INTACS:

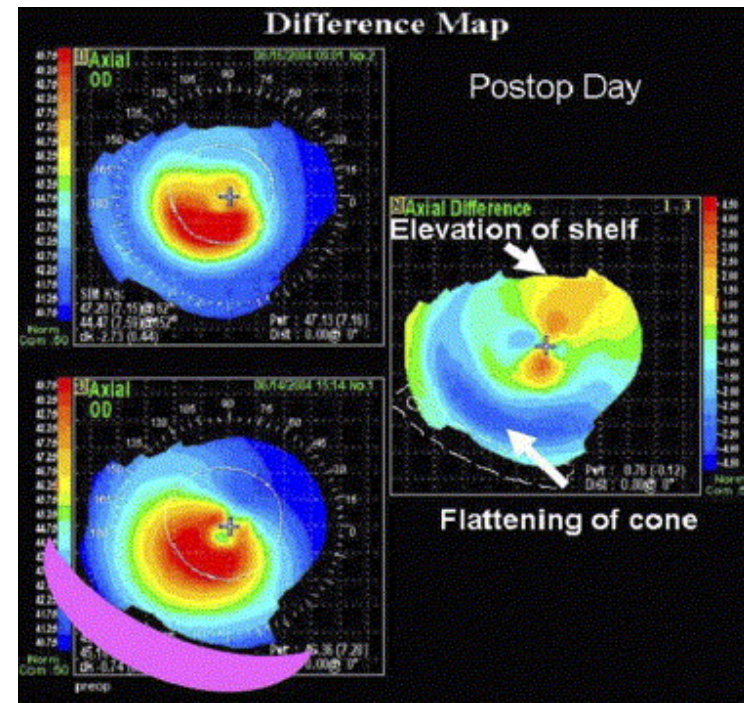
Segment Choice and Location

- Placement of rings – Multiple options:
 - Incisions on the steepest axis to reduce astigmatism
 - Incisions temporally and asymmetric sizes of segments
 - Incisions made to bisect the segments at the thinnest area of the cornea in order to thicken a thin area
 - Segments centered over the cone and not the center of the cornea
 - Vertical Intacs implantation based on the ease of manipulation from a 12 o'clock incision



INTACS: Single Segment vs. Double Segment

- Patients with KCN tend to have an inferior cone with steepening and flattening superiorly.
- Double segments flatten both inferiorly and superiorly which does not address the issue of asymmetric astigmatism
- Single segments flatten inferiorly and steepen superiorly
- Consider single-segment INTACS for peripheral cones and double-segments for centrally located cones for improved visual and topographic outcomes



Intrastomal Corneal Ring Complications

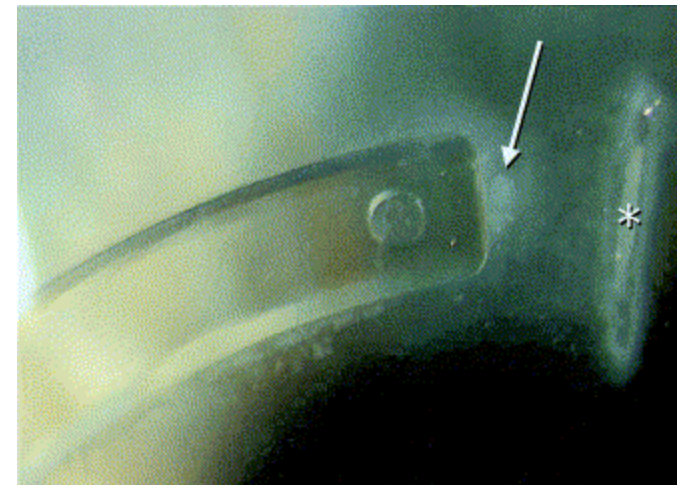
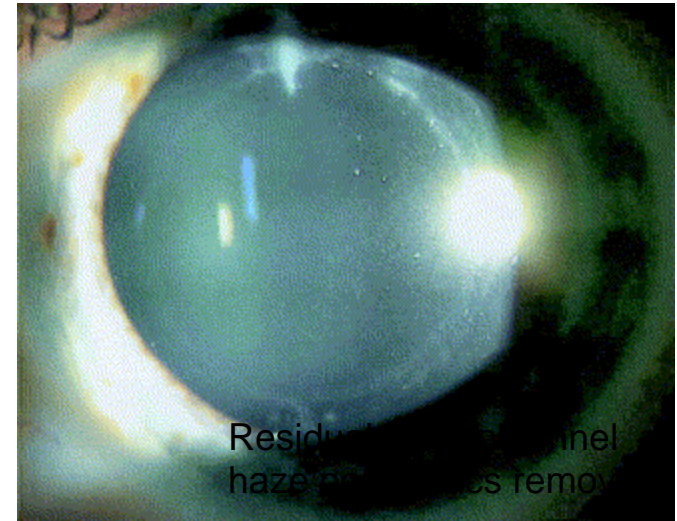
- European multicenter study of intrastomal corneal ring segments (2001)
 - 1 year data; 163 eyes of 110 patients for myopia
 - Intraoperative complications 2% of eyes (4/163)
 - 3 eyes with anterior surface perforations
 - 1 eye with posterior microperforation

Intrastomal Corneal Ring Complications

- European multicenter study of intrastomal corneal ring segments (2001)
 - 2 incisional gapes:
 - 1 healed without complications
 - 1 ISCR removed at 3 months post-op due to non-healing incision
 - 4 eyes required repositioning of ISCR
 - 1 eye with a channel infection 3 weeks post-op
 - Stromal thinning 2% of eyes at 1 month

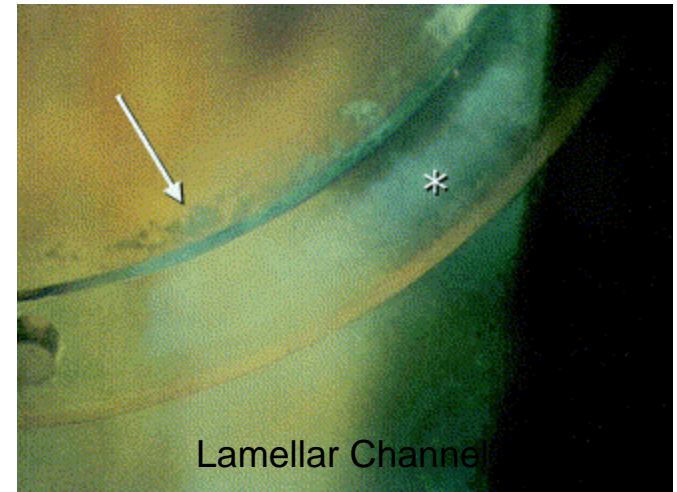
Intrastomal Corneal Ring Complications continued

- Diffuse haze under stromal tunnel medial and lateral to the segments
 - Gradually decreased with time; did not spread beyond the edge of the tunnel
 - No affect on visual outcome
- Epithelial cysts at the incision site in 7% of eyes (11/156)
 - Lasted 7 days to 3 months; 1 eye at 12 months

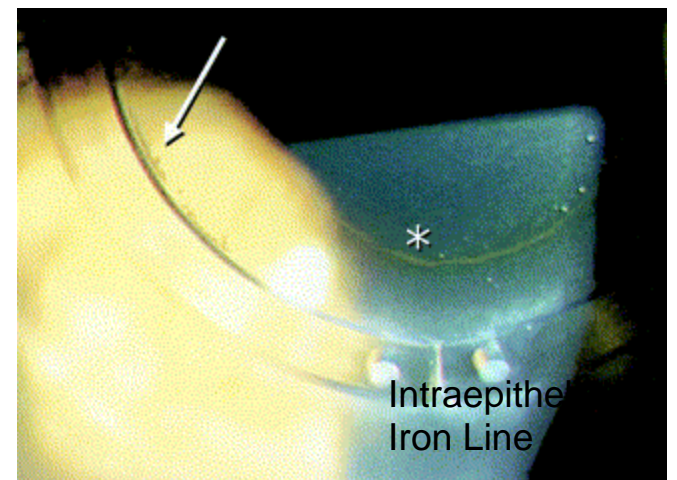


Intrastomal Corneal Ring Complications continued

- Lamellar channel deposits along the inner or outer curvatures of the ISCR
 - Developed within the 1st months post-op
 - No clinical impact



- Intraepithelial iron line occurred in most eyes 6-9 months post-op



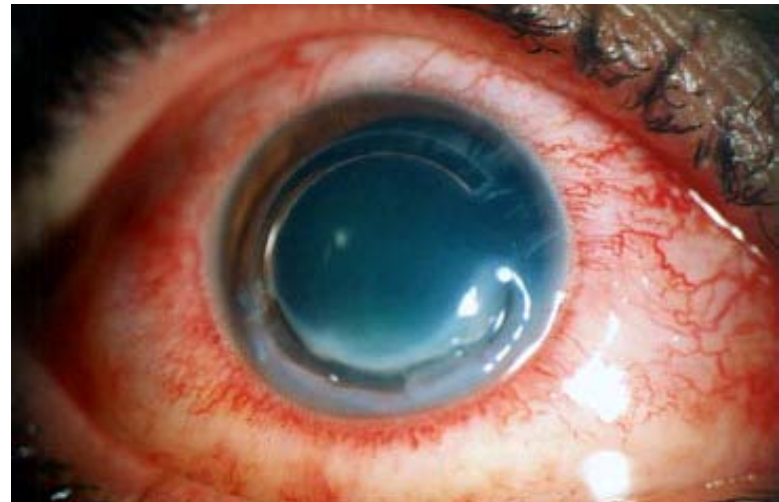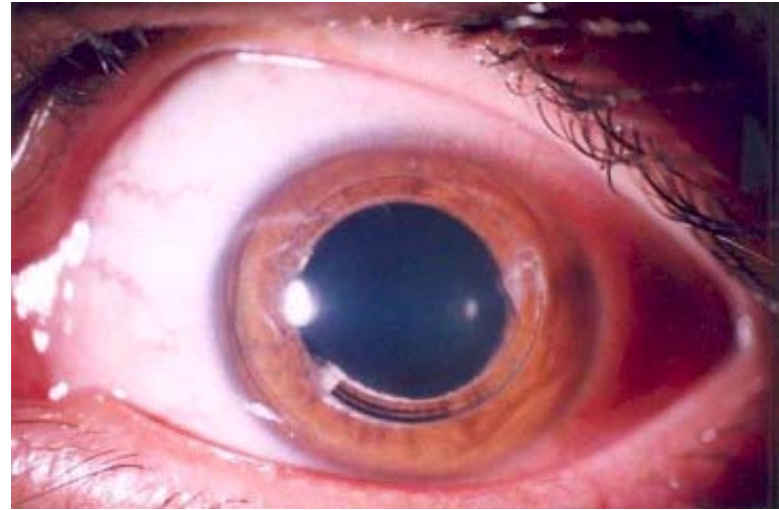Intrastomal Corneal Ring Complications continued

– Visual symptoms:

- Mild-moderate post-op pain
 - FBS, photophobia in first 24-48 hours
 - Typically, no visual symptoms by 12 months
- Severe glare occurred within the first 2 months
 - < 4% of eyes
 - By 12 months, 96% had no or mild glare

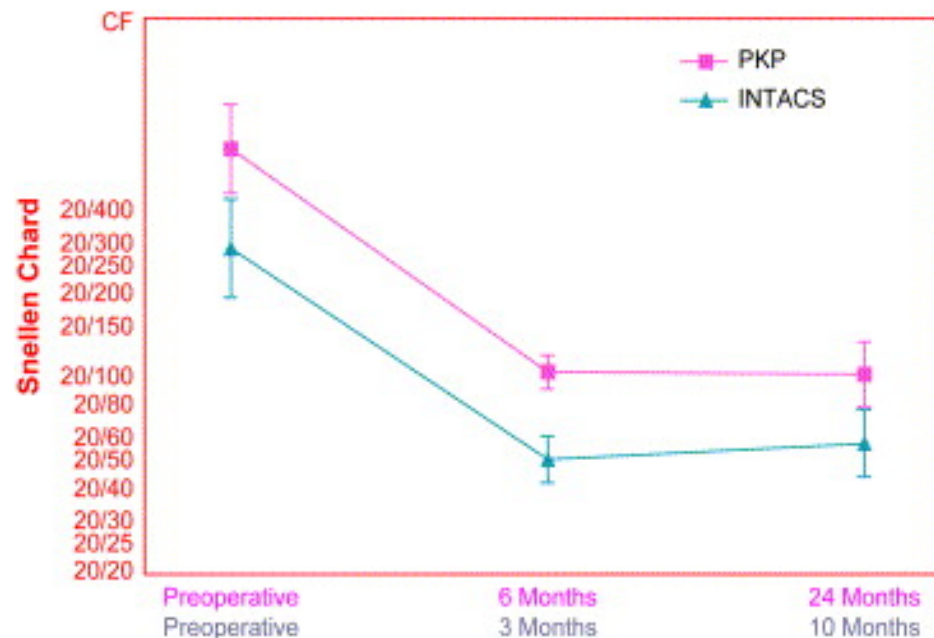
INTACS: Complications

- Zare et al, 2007 – 30 eyes with KCN:
 - 3 cases of ISCR movement and exposure, 3-5 months post-op
 - 2 cases of repeated exposure and significant corneal thinning over the ring segments
 - 1 case of severe FBS / discomfort
 - 1 case of corneal melting and severe corneal infiltration required segment removal and fortified antibiotic drops



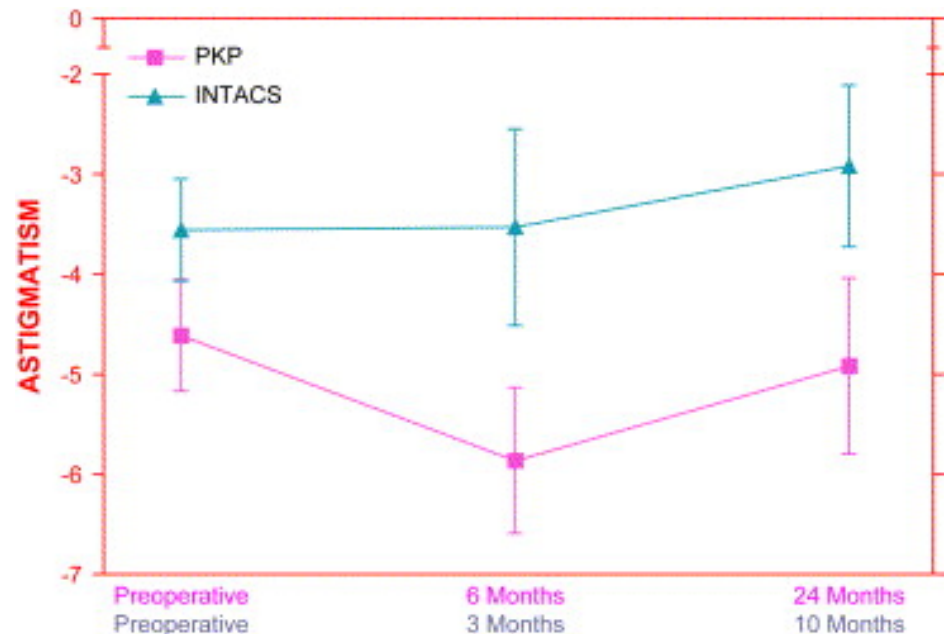
PKP vs. INTACS

- Rodriguez et al, 2007
 - Nonrandomized, retrospective comparison
 - 17 pts with PKP in one eye and Intacs in other
- Uncorrected vision
 - Less time to reach potential visual acuity
 - Statistically significant improvement in UCVA with both INTACS and PKP



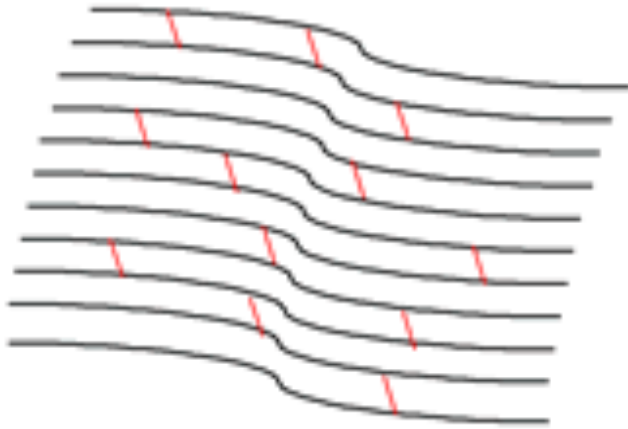
PKP vs. INTACS continued

- Astigmatism
 - BCVA better at 3 months with INTACS, but not statistically significant at 10 months
 - Astigmatism lower at 10 months with INTACS, but not statistically significant

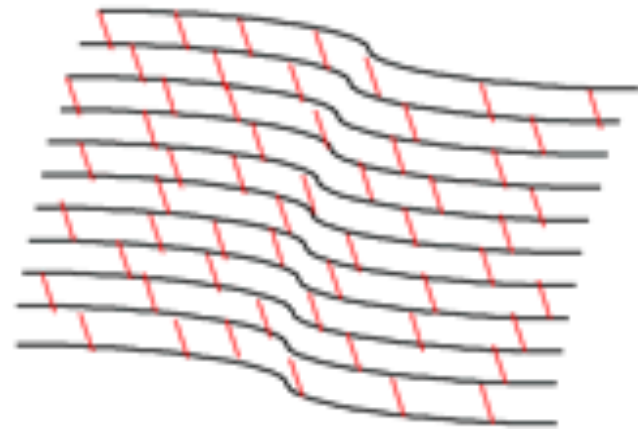


Collagen Crosslinking (CXL)

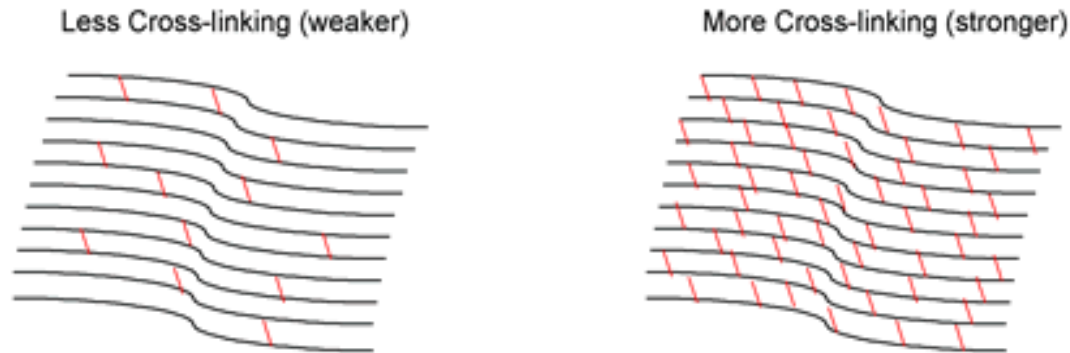
Less Cross-linking (weaker)



More Cross-linking (stronger)




Collagen Crosslinking (CXL)



- Studies of keratoconic corneas have demonstrated lower corneal elasticity and ocular rigidity in keratoconic eyes compared to normal corneas
- Decreased stiffness and elasticity of the cornea in keratoconus is thought to be related to a reduction in collagen cross-linking

CXL

- Improves the biomechanical properties of the cornea by strengthening the corneal tissue in the anterior stroma.
- The only procedure available to specifically stop the progression of keratoconus and strengthen the individual collagen fibers in the cornea.



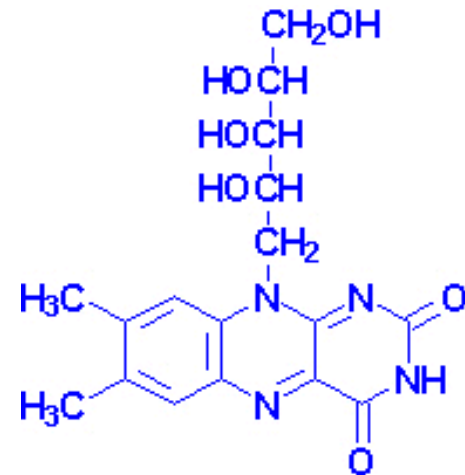
CXL

- Corneal stromal crosslinking investigations began in mid 1990s as a conservative treatment for keratoconus
 - The biomechanical behavior of the cornea could be altered by irradiation using ultraviolet light with photosensitizers and by aldehyde reactions (Spoerl and Seiler).
 - Porcine corneas treated with either glutaraldehyde, Karnovsky's solution (glutaraldehyde and paraformaldehyde) or riboflavin and UV-irradiation.
 - Compared to untreated corneas, these treatments caused an increase in corneal stiffness.



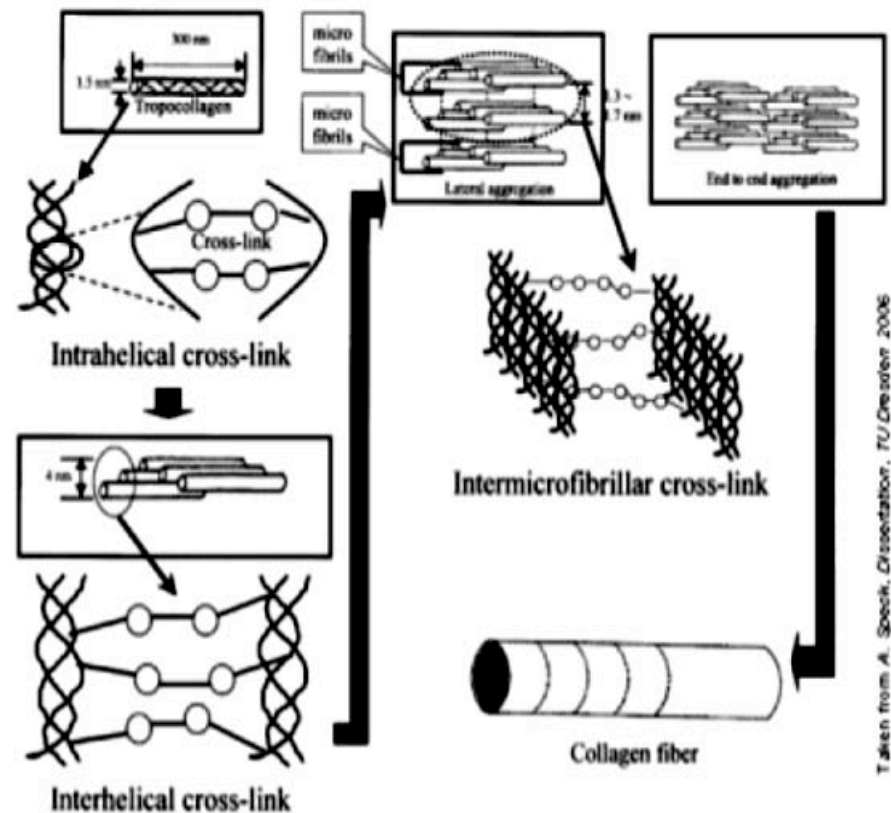
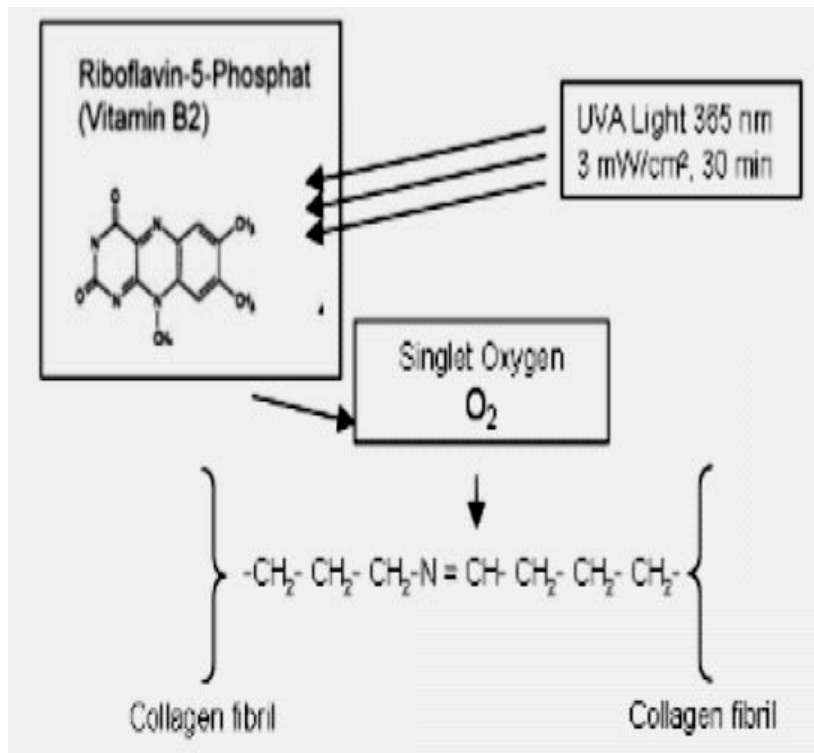
CXL

- UV-radiation alone did not induce mechanical changes in the cornea, but required a photosensitizer
- Riboflavin is a non-toxic photosensitizer
 - Vitamin B2
 - Soluble in water
 - Non-mutagenic
 - Penetrates easily into the corneal stroma in the absence of epithelium



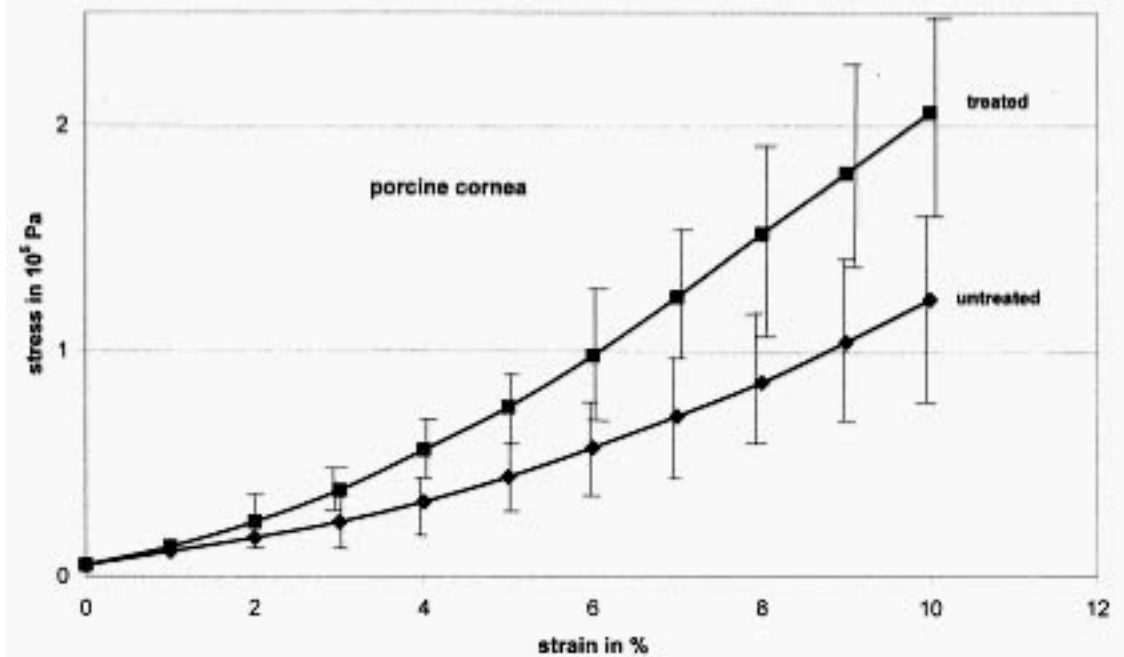
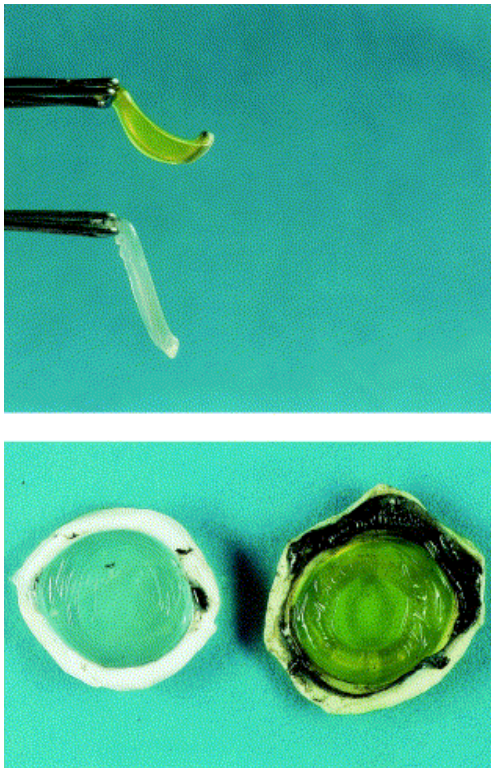
CXL

- Riboflavin is activated by UV-A radiation which generates singlet oxygen and superoxide free radicals that results in crosslinking of the collagen fibers



Collagen Crosslinking: Biomechanical testing

- Significant increase in corneal rigidity by ~70% in porcine corneas treated with riboflavin + UVA
 - Wollenski, Spoerl and Seiler

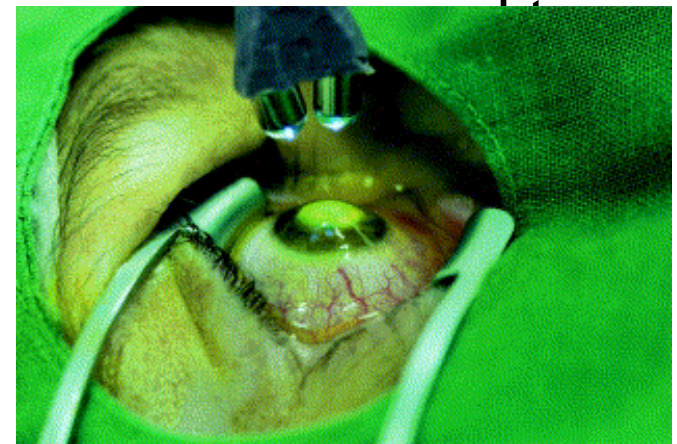






CXL

- Wollensak et al were the first to develop and introduce this new technique of collagen crosslinking.
- Pilot study 2003 with 23 eyes of 22 patients
 - Prospective, non-randomized study
 - Inclusion criteria:
 - Clinical diagnosis of keratoconus based on corneal topography and signs such as stromal thinning, Fleischer ring, Vogt striae, apical stromal scar
 - All patients showed preoperative progression of keratoconus

CXL

- Treatment Procedure
 - 7mm central corneal epithelium removed
 - Riboflavin 0.1 % applied 5 minutes prior to irradiation and every 5 minutes during irradiation treatment
 - 2 UVA-light diodes (370nm) irradiate the cornea at distance of 1 cm for 30 minutes
 - Antibiotic ointment applied post-treatment

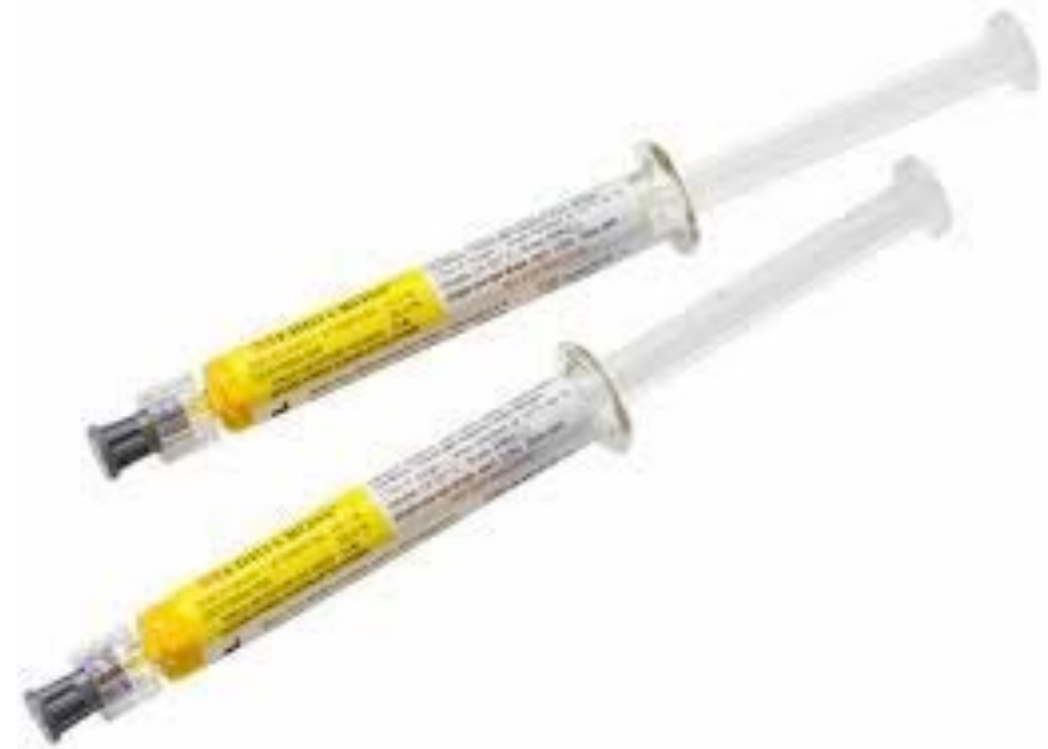
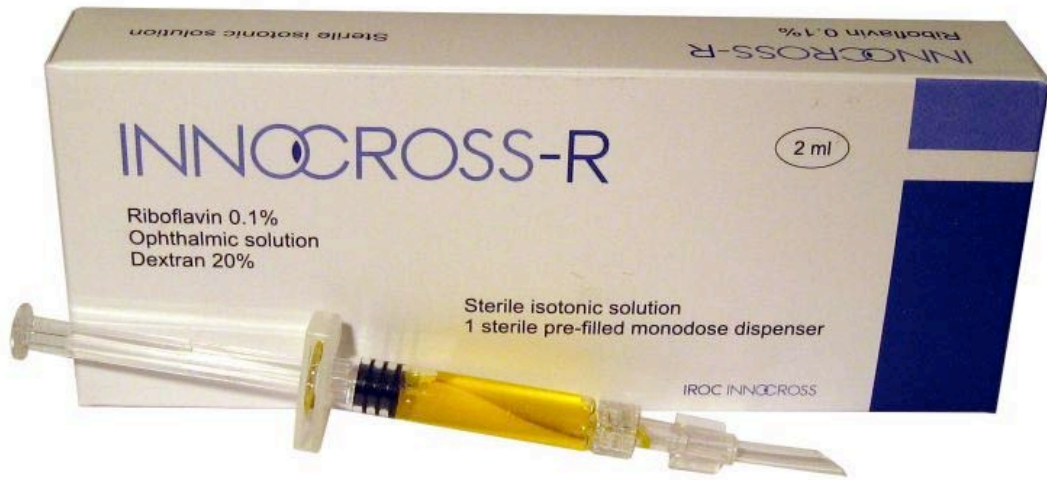
	Avedro	Peschke	OFTA Hi-Tech	IROC
UV-A Light Source	KXL	CCL365	Vega	UV-X
				
CE Mark	Yes	Yes	Yes	Yes
UV-A Wavelength	365 nm	365 nm	370 nm	365 nm
Power Output	3mW/cm² to 45mW/cm²	3mW/cm²	3mW/cm² ± 10%	3mW/cm²
Energy density	Controlled to 5.4J/cm²	5.4J/cm²	5.4J/cm²	5.4J/cm²
Beam Diameter	7mm to 11mm	7mm to 11mm	4mm to 9mm	7mm - 11mm
Other Features	Touch Screen Programming Internal UV Monitor Remote Control Wireless, Positioning in x, y, and z axis Battery or Wall Power	Supplied with a suit-case for portability	Micro-telecamera LCD monitor	UV light meter delivered with UV-X system
Cross-linking Time	Less than 3 minutes	Up to 30 minutes	Up to 30 minutes	Up to 30 minutes
Riboflavin	0.1%	0.1%	0.1%	0.1%

PESCHKE MEDITRADE GmbH

new





Guidelines for CXL

- Patients with progressive Keratoconus
- Minimum corneal thickness of 300 microns to protect the epithelium
- Maximal keratometry readings < 60 D
- No other corneal disease
- Patients over the age of 16 years but under 35 years old

Guidelines for CXL

- Corneal epithelium should be removed to facilitate diffusion of riboflavin through the stroma
 - Pinelli, 2008 evaluated whether or not this step is necessary
 - 10 eyes (5 with intact epithelium, 5 depithelized)
 - At 6 and 9 months post-op, no significant difference between 2 groups
 - De-epithelized group showed demarcation lines in stroma
 - Post-operatively, non-depithelized group had significantly less discomfort and did not require topical steroids
- 0.1% riboflavin solution should be applied 30 minutes prior to UV exposure
- Homogenous UV irradiance of 3 mW/cm² and wavelength of 370 nm
 - Serves as both a photosensitizer and a UV blocker

CXL

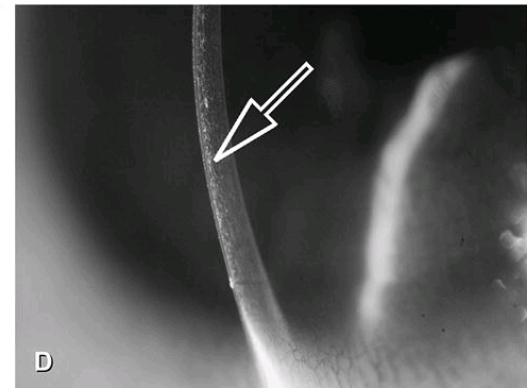
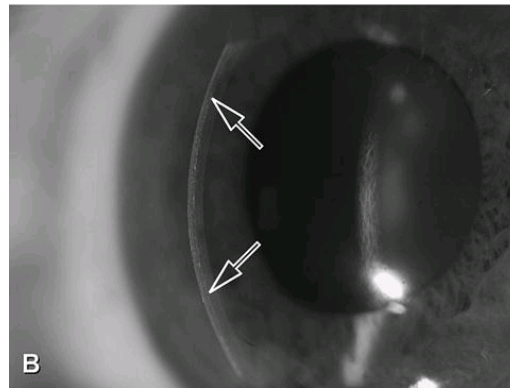
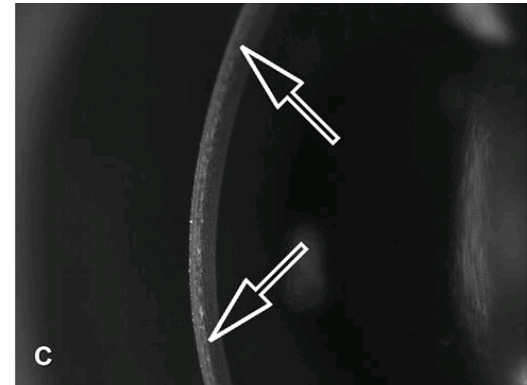
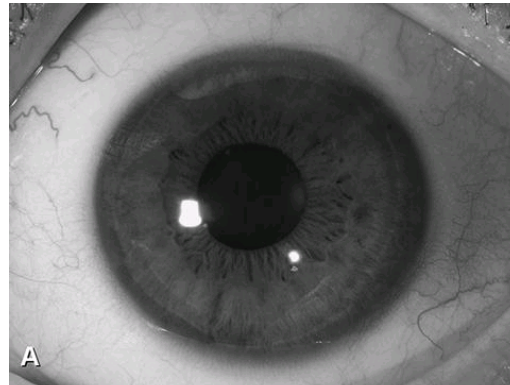
- Postoperative healing unremarkable with slight transient stromal edema until reepithelialization
- No significant side effects
 - No corneal scarring
 - No persistent epithelial defects
 - No change in corneal and lens transparency, no cataract formation
 - No change in endothelial cell density
 - No effect on postoperative contact lens use

CXL

- Stromal haze has been reported after CXL treatment
 - In a series of 40 eyes of 39 patients, two cases of stromal haze developed in patients with stage III keratoconus
 - Occurred between the 2nd and 3rd post-operative months
 - Resistant to topical steroids; unchanged at post-op month 6
 - Pre-operative confocal analysis showed reticular hyporeflective microstriae in these two patients
 - Post-operative confocal analysis showed an increase in keratocyte population at a 170-200 μm depth
 - Stromal haze did not impair BCVA post-operatively

Collagen Crosslinking

- Stromal demarcation line has been reported after C3-R treatment
 - Thin stromal demarcation line over the whole cornea at a depth of $\sim 300 \mu\text{m}$
 - Visible beginning 2 weeks after treatment
 - No other side effects were noted to the corneal endothelium, the lens, or IOP
 - ? Change in refractive index between untreated and treated cornea vs. reflection properties of treated and untreated cornea



CXL - US clinical trial

- First U.S clinical trial to study collagen cross-linking with riboflavin from December 2007 to April 2011
- Data has been collected and the results are pending
- R. Doyle Stulting, MD, PhD - principal investigator for the clinical trial

CXL - US clinical trial

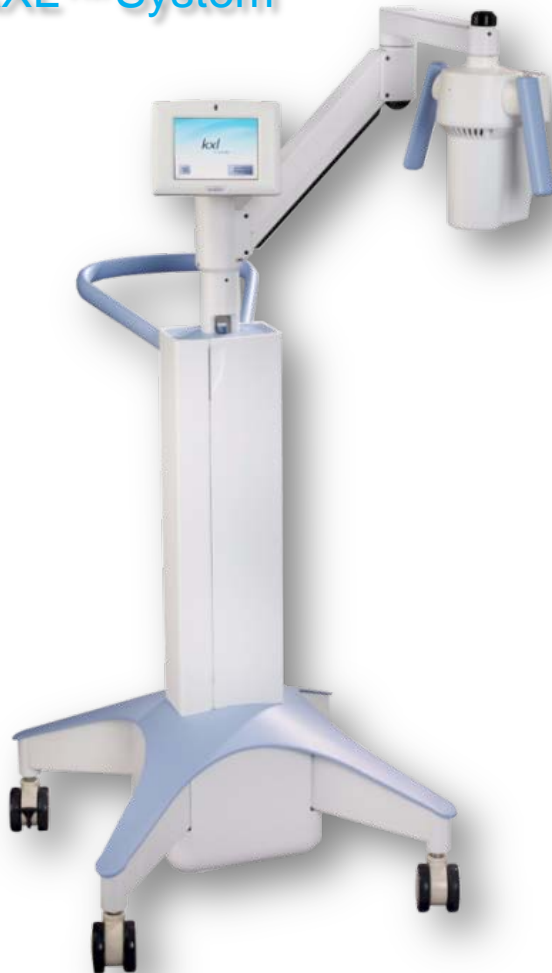- Two prospective, randomized, parallel-group, open-label, sham-controlled, 12-month trials
- Goal - to determine the safety and effectiveness of performing CXL with progressive keratoconus or corneal ectasia following refractive surgery.
- A single application of riboflavin ophthalmic solution / UVA irradiation used.
- Two multicenter studies
 - progressive keratoconus
 - corneal ectasia

CXL - US clinical trial

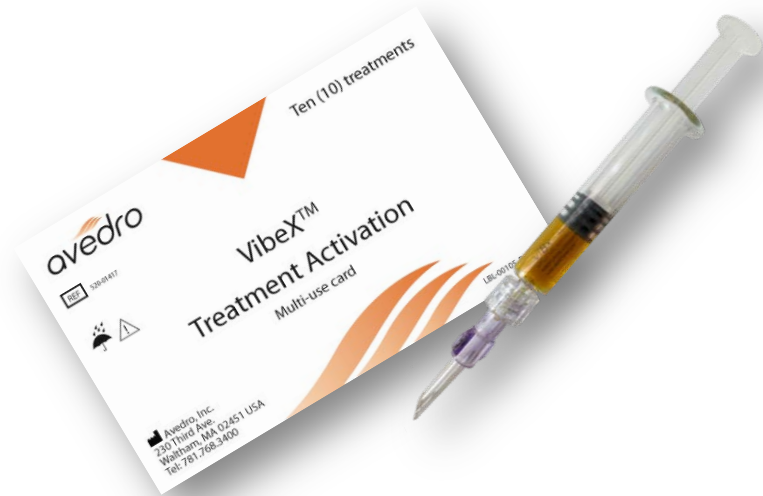- Two multicenter studies
 - Progressive keratoconus
 - Corneal ectasia
- Planned Sample Size
 - 160 eyes with progressive keratoconus
 - 160 eyes with corneal ectasia
 - 10 sites randomized in 1:1 ratio of active : control
- Sponsored by the Swiss-based company, Peschke Meditrade GmbH and then the US-based company, Avedro

Avedro's Cross-Linking Products

KXL™ System

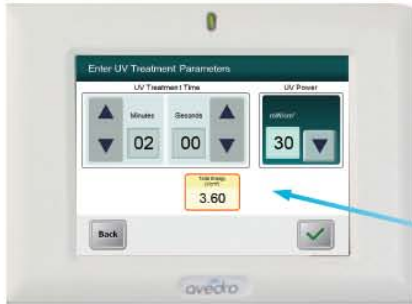

RFID Card & Riboflavin

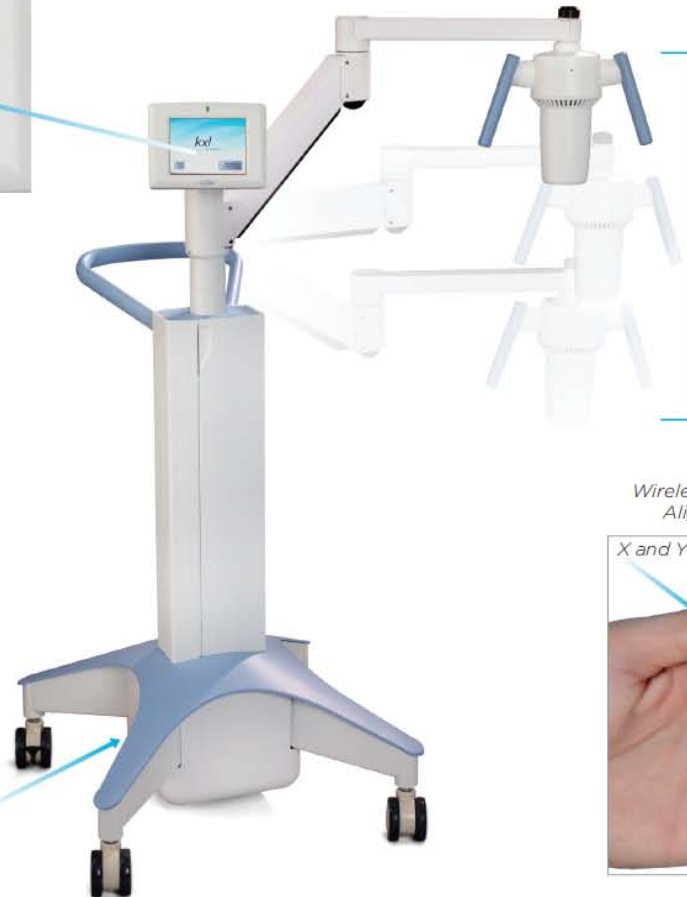

- CE Marked
- FDA Orphan Drug Designation

Avedro's KXL System



Touch Screen Monitor for Procedure Programming and Device Operation



Effortless and Stable Beam Positioning

Wireless Control for Fine Beam Alignment and Focusing




Rechargeable Battery for Cordless Operation

CXL - US clinical trial

- **Primary Efficacy Criteria**
- Mean change in Kmax of ≥ 1 diopter (D) between the CXL treatment group and the control group from baseline to 12 months.
- **Schedule of Assessments**
- Screening / baseline
- Day 0 (randomization / treatment day)
- 1 day
- 1 week
- 1, 3, 6 and 12 months after treatment

Treatment Groups



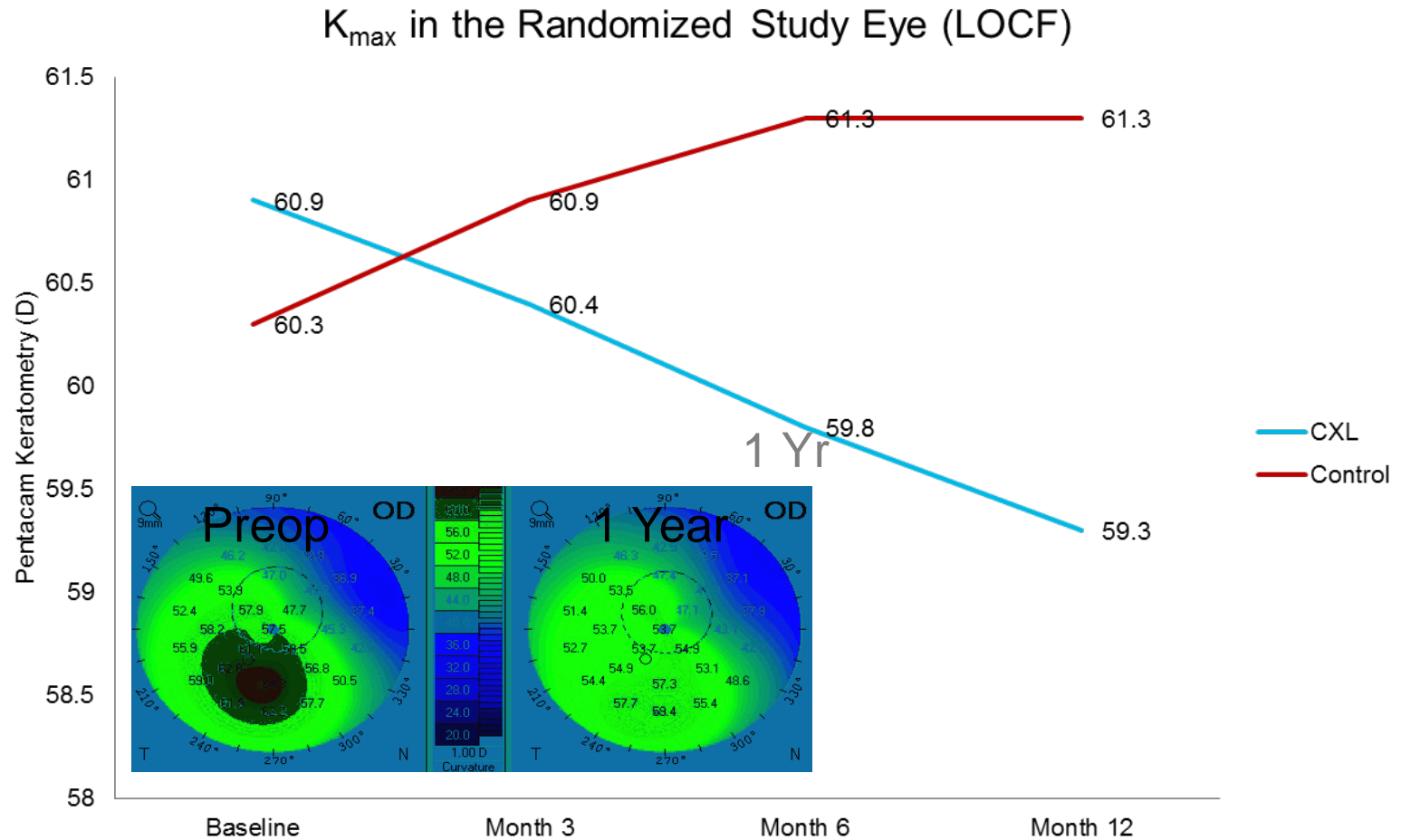
Keratoconus and Corneal Ectasia

Total Eyes Enrolled & Treated

Randomization	Primary (Study) Eye		Secondary Eyes		Total
	CXL	Sham	Fellow Eye CXL	Sham Eye CXL	
Keratoconus					
Subjects Randomized to CXL	102	---	56	---	---
Subjects Randomized to Sham	---	103	41	94	---
TOTAL CXL	102	---	97	94	293
Ectasia					
Subjects Randomized to CXL	91	---	26	---	---
Subjects Randomized to Sham	---	88	22	80	---
TOTAL CXL	91	---	48	80	219

Safety and Efficacy Analyses

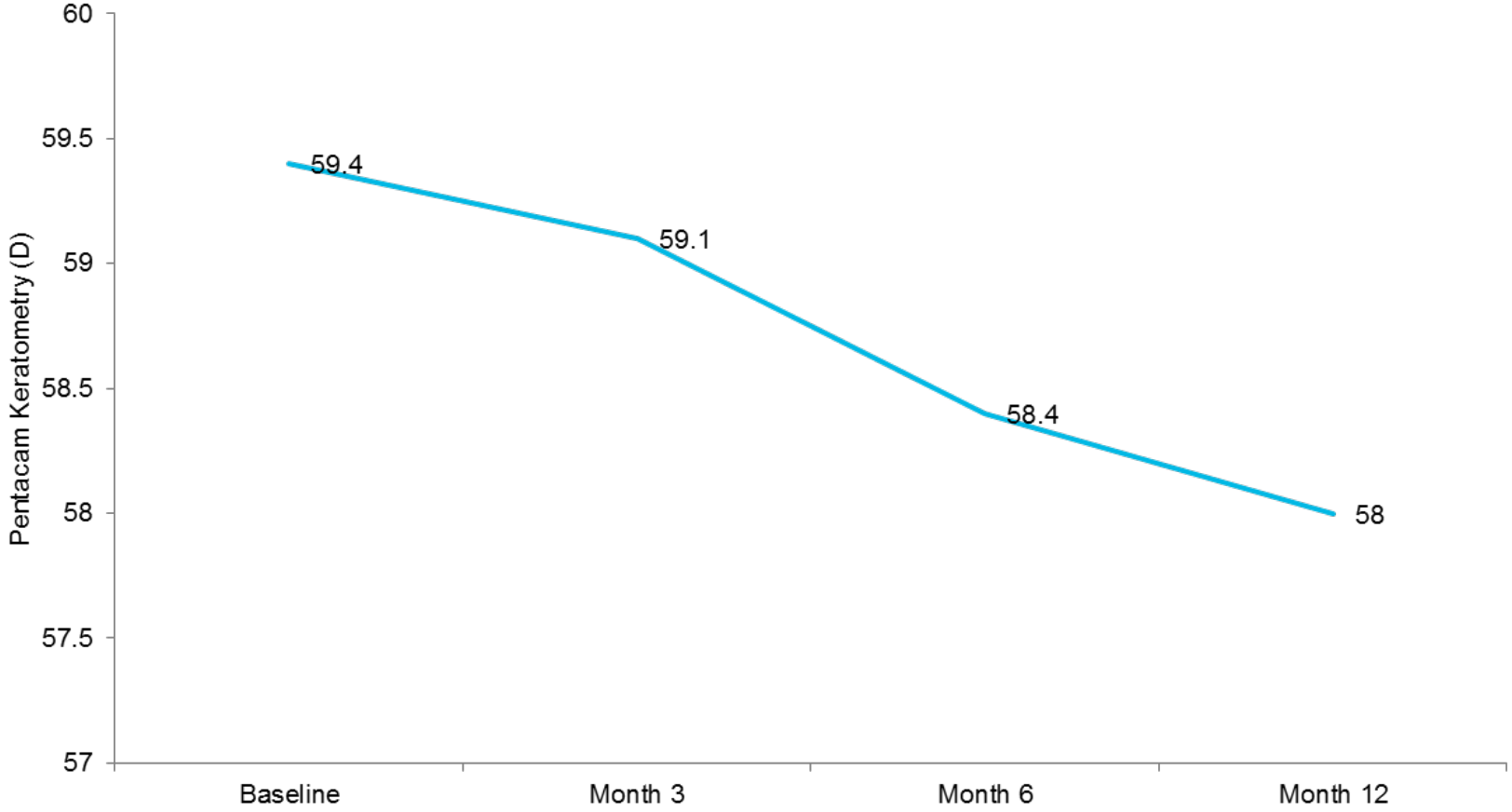
KCN CXL Clinical Time course – Randomized Eyes Only (LOCF)



*LOCF = Last Observation Carried Forward

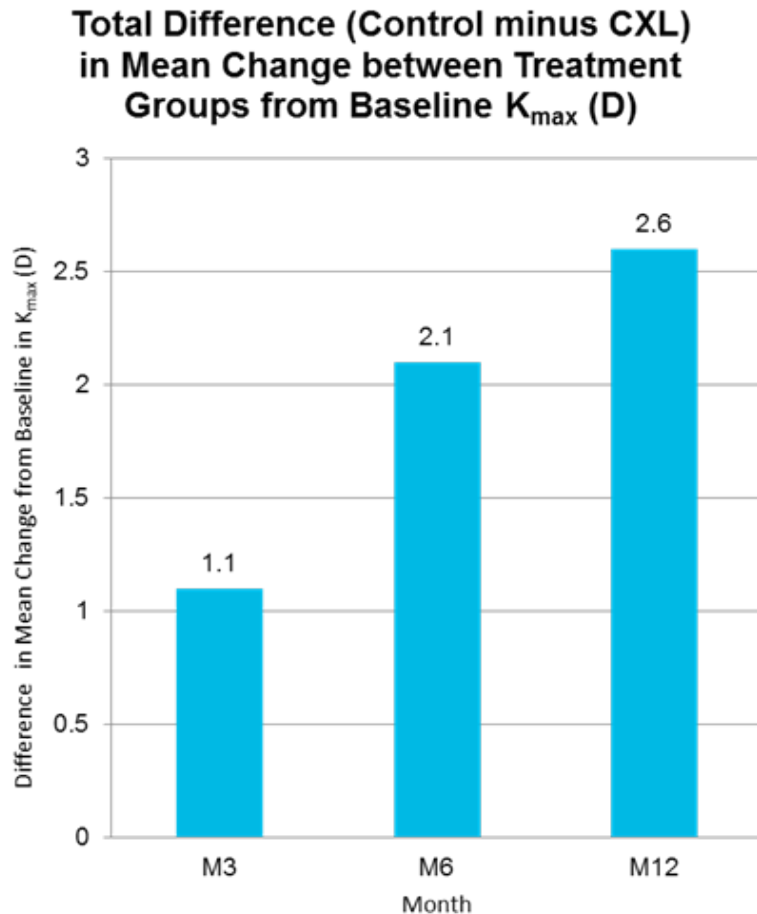
KCN CXL Clinical Time course – All CXL Eyes

K_{max} (D) in all CXL-Treated Eyes(LOCF)



*LOCF = Last Observation Carried Forward

KCN: Total Difference between Active and Control Groups



LOCF imputation was used

- The difference between CXL and control groups in the mean change from baseline K_{max} progressively improved, in favor of CXL
- Improvement met the definition of success (i.e. a difference between treatment groups of $\geq 1D$ in the mean change in K_{max} from baseline) at Months 3, 6, and 12
- The difference between treatment groups in mean change from baseline K_{max} was statistically significant at month 12 ($p < 0.0001$)

CXL - US clinical trial

- At 3 to 6 months, subjects given the option to perform CXL on untreated fellow eyes and eyes that were randomized to the control group.
- Only if no contraindications with the CXL treatment.
- All eyes were followed for 12 months after the CXL procedure.

Conclusions

- CXL treatment decreases the progression of keratoconus and corneal ectasia
- CXL impedes the progressive loss of vision that naturally occurs in KCN and ectasia and which may necessitate corneal transplantation

Conclusions

- CXL procedure with riboflavin provided statistically significant and clinically meaningful effects
- CXL treatment was safe and well tolerated in subjects
- CXL offers a safe and clinically meaningful treatment for these corneal disorders that currently have no FDA-approved therapeutic treatment

Thank You!

Please feel free to contact me with any questions

Melissa Barnett, OD, FAAO

drbarnett@ucdavis.edu

916-734-7851